



Evaluation of pulmonary maturity in bovine neonates: analysis of amniotic fluid¹

Gabriela N. Dantas^{2*} , Bianca P. Santarosa² , Vitor H. Santos³,
Fernando J. Benesi⁴ and Roberto C. Gonçalves²

ABSTRACT.- Dantas G.N., Santarosa B.P., Santos V.H., Benesi F.J. & Gonçalves R.C. 2019. **Evaluation of pulmonary maturity in bovine neonates: analysis of amniotic fluid.** *Pesquisa Veterinária Brasileira* 39(8):600-605. Departamento de Clínica Veterinária, Faculdade de Medicina Veterinária e Zootecnia, Universidade Estadual Paulista, Distrito de Rubião Júnior s/n, Botucatu, SP 18618-970, Brazil. E-mail: gabrielan.dantas@gmail.com

Considering the representativeness of dairy cattle in our country, the concern about the mortality rates of the animals increases each time. Regarding to calf mortality, the Respiratory Distress Syndrome (RDS) has an important relevance during the neonatal period, and it is present in immature lungs. The amniotic fluid is in direct contact with the fetus, and it is able to offer evidence about his maturity. The aim of this study was to standardize the characteristics of the amniotic fluid, color, aspect, viscosity, quantification of lamellar body and surfactant evaluation by the Clements test and cytology, of term-born, mature and healthy calves. There were used 50 Black and White Holstein calves, which mothers were observed at calving in order to collect the amniotic fluid by puncture in the moment of exposure of the fetal membrane through the vaginal canal. Most amniotic fluid had a clear and hazy appearance due to varying degrees of viscosity and the presence or absence of clots. The Clements test could be adapted to the bovine species by the modification consisting in the addition of 3mL of amniotic fluid and 1mL of 95% ethanol. The methodology of the lamellar body count by the automated particle counter is not applicable for the bovine because of the small size of their lamellar body. The Nile Blue staining is unsatisfactory on predicting fetal maturity on the bovine species, different from cytology using Hematoxylin-Shorr stain. The presence of orange cells, increase in large amounts at the end of pregnancy. The cell stained orange counting, cells which are found in great amounts at the end of pregnancy. The present study established new parameters for evaluation of fetal and pulmonary maturity in the bovine species.

INDEX TERMS: Evaluation, pulmonary maturity, bovine neonates, analysis, calf, fetal maturity, lamellar bodies, Clements test, amniotic fluid, cytology.

¹ Received on February 22, 2019.

Accepted for publication on March 31, 2019.

Master's Thesis of the first author. Financed by "Fundação de Amparo à Pesquisa do Estado de São Paulo" (FAPESP) through scholarship (Proc. 2012/24836-8).

² Departamento de Clínica Veterinária, Faculdade de Medicina Veterinária e Zootecnia (FMVZ), Universidade Estadual Paulista (Unesp), Distrito de Rubião Júnior s/n, Botucatu, SP 18618-970, Brazil. E-mails: bिकासantarosavet@gmail.com, calderonmedvet@gmail.com; *Corresponding author: gabrielan.dantas@gmail.com

³ Departamento de Cirurgia e Anestesiologia Veterinária, Faculdade de Medicina Veterinária e Zootecnia (FMVZ), Universidade Estadual Paulista (Unesp), Campus de Botucatu, Distrito de Rubião Júnior s/n, Botucatu, SP 18618-970, Brazil. E-mail: vitor.santos@grupointegrado.br

⁴ Departamento de Clínica Médica, Faculdade de Medicina Veterinária e Zootecnia (FMVZ), Universidade de São Paulo (USP), Av. Dr. Orlando Marques de Paiva 87, Cidade Universitária, São Paulo, SP 05508-270, Brazil. E-mail: febencli@usp.br

RESUMO.- [Avaliação maturidade pulmonar em neonatos bovinos: análise do líquido amniótico.] O objetivo desse estudo foi reunir novos dados práticos sobre a avaliação da maturidade pulmonar em neonatos bovinos, padronizando as características do líquido amniótico de bezerros maduros e hígidos, o que proporcionará a oportunidade de tratamento precoce dos animais prematuros, evitando prejuízos econômicos, principalmente quando consideramos os animais de alto valor genético. Amostras de líquido amniótico foram coletadas de 50 vacas da Raça Holandesa Preta e Branca. Corpos lamelares foram identificados por microscopia eletrônica de transmissão como estruturas de tamanho aproximado de 130nm, o que impede sua contagem em analisadores automáticos. O teste de Clements sofreu adaptações de técnica e se mostrou viável com a diluição de 3mL de líquido amniótico em

1mL de etanol a 95%. A citologia utilizando o método de Hematoxilina-Shorr, diferentemente do teste de Azul de Nilo, foi eficaz na identificação das células orangiofílicas, indicativas de maturidade fetal. Esses métodos mostraram-se originais e úteis ferramentas para a avaliação de maturidade pulmonar na espécie bovina, porém estudos com bezerros prematuros ainda são necessários.

TERMOS DE INDEXAÇÃO: Avaliação, maturidade pulmonar, neonatos bovinos, análise, bezerro, maturidade fetal, corpos lamelares, teste de Clements, citologia, líquido amniótico.

INTRODUCTION

Lung maturation at birth coincides with fetal maturity and is directly related to surfactant production (Eigenmann et al. 1984). The function of surfactant is to reduce surface tension at the air-liquid interface of the alveoli, preventing their collapse and facilitating the newborn's respiratory work (Rebello et al. 1996). The consequence of pulmonary immaturity is respiratory distress syndrome (RDS), or neonatal asphyxia, which causes economic and genetic damage to breeding due to animal death (Benesi 1993).

In the last decade, studies have been conducted to clarify the effectiveness of tests to determine the stage of pulmonary development, being most of them with application to the human species (Gil et al. 2010). Research of this scope is scarce in veterinary medicine, and most of these data do not exist for the bovine species.

The tests used to assess fetal and pulmonary maturation from amniotic fluid samples can be summarized as follows: Nile Blue Sulfate or Hematoxylin-Shorr cell staining, which indicates immaturity (Martins & Prestes 2003); test of Clements, a qualitative method that indicates the formation of a complete or incomplete bubble ring due to the saponification reaction present, whether or not there is, respectively, adequate surfactant in the amniotic fluid (Barreto et al. 2011); lamellar body count, the phospholipid reservoirs, components of the pulmonary surfactant, present in the amniotic fluid, which is performed in an automatic hematological counter in the platelet count channel, due to the equivalent size of these structures (Gil et al. 2010). For the lamellar body count to be applied to the bovine species, they must necessarily have the same size as the platelets, so that the hematology analyzer can perform the exam. As the size and appearance of these structures in bovine are not known, it is necessary to perform electron microscopy in amniotic fluid of the bovine species in order to initially recognize the lamellar bodies before testing the applicability of the test.

Amniotic fluid is an important component of the intrauterine environment. It provides a wealth of information on fetal health and maturation as it is in direct contact with its respiratory tract and skin, thus reflecting the amount of surfactant present and the predominant cell type in its epithelium (Campana et al. 2003).

Thus, this work aimed at contributing to the improvement of techniques for measuring the degree of pulmonary maturity in bovine by analyzing the characteristics of the amniotic fluid as to coloration, appearance, viscosity, presence of surfactant by Clements test, evaluation of lamellar bodies and cytology of Black and White Holstein calves born mature, term and healthy, prioritizing tests of practical application

in the clinical routine. Thus, a study that standardizes the characteristics of the amniotic fluid of mature calves will provide the opportunity for early treatment of premature animals, avoiding economic losses to the breeder, especially regarding to animals of high genetic value, *in vitro* fertilization products (IVF) and cloning. In addition, understanding and standardizing indicators of physiological pulmonary maturation through the abovementioned diagnostic tests will contribute to the understanding of the pathogenesis of RDS in bovine species, a necessary prerequisite for the development of therapeutic tools that mitigate or prevent lung lesions and the death of animals as a result of the syndrome.

MATERIALS AND METHODS

Fifty healthy Black and White Holstein newborn calves (30 females and 20 males) from a farm located in Descalvado/SP born from artificial insemination were used. Females of advanced gestational age were kept in semi-intensive regime in the farm's Maternity Sector. The collections were performed from February to June 2014. All deliveries were accompanied. Twice a day the paddocks were inspected for animals with signs of imminent calving, and cows with deliver scheduled to that week were separated from the flock. The selected animals were kept in farrowing pens where the support staff monitored them 24 hours a day.

In order for newborns to be classified as healthy and mature, they were evaluated at birth considering the following aspects: gestation duration and mother's health; size of the newborn; screening by Apgar score (Born 1981) in the first minute of life with selection of only 7 or 8 newborns; general physical examination (Feitosa & Benesi 2014); and blood pH measurement by jugular vein puncture in a portable blood gas meter (I-STAT[®], Abbott Laboratories, Illinois, USA). Any evidence of prematurity, immaturity, disease, low vitality or contamination of amniotic fluid by meconium, were exclusion factors in this study.

Amniotic fluid samples (20mL) were collected during labor with the aid of a 20mL syringe and 40×12 needle by puncture and aspiration of the amniotic sac at the time it was exposed in the birth canal. The collected volume was transferred to a dry 30mL polyethylene tube and immediate tests were performed (analysis of color and appearance, and Clements test). The remaining material was transferred to identified *Eppendorf* tubes, kept at 20°C until further testing (lamellar body analysis and cytology).

For color and appearance analysis, the liquid was rated for color (light, yellowish or reddish), appearance (cloudy or not) and viscosity (low viscous/+, viscous/++ or very viscous/+++). In addition, the presence or absence of lumps was recorded. The original Clements test (Clements et al. 1972), modified by Barreto (Barreto et al. 2011) and technique adapted by the authors of this work were performed, which consisted of mixing 3mL of the amniotic fluid sample with 1mL of ethanol at 95% and performing the subsequent steps similarly to the original Clements test. The technique used for lamellar body counting was standardized for automatic counters (Neerhof et al. 2001). For the transmission electron microscopy processing, the collected material was fixed in Karnovsky solution (8% paraformaldehyde, 25% glutaraldehyde and 0.2M phosphate buffer at pH 7.3 in a 5:1:4 ratio) and kept at room temperature for 4 hours. After the fixation time, the material was refrigerated at 4°C until processing, performed on a 150-200 mesh carbon film copper grid and stained with 4% uranyl acetate. The material examination was performed under a transmission electron microscope Tecnai[®]. For cytology using Nile Blue, one drop (50µl) of amniotic fluid and one

drop of 0.1% Nile Blue dye were added to the slide, then mixed. After covering with a slide, the optical microscope reading was performed. Five fields were counted and the absolute and relative frequency of each cell type (orangiophilic and cyanophilic) was recorded. For staining using the Hematoxylin-Shorr technique, the methodology proposed by Moya (2005) was used, and after slide preparation, a reading similar to the Nile Blue method was performed.

Regarding the statistical analysis, all variables had their distribution analyzed for normality. Continuous variables were initially submitted to descriptive statistics. Frequency distributions were produced to present the results of nominal and ordinal variables. To compare the mean blood pH between animals from dystocia and eutocic births, the unpaired t-test was used. To estimate the correlation between the proportion of orange and blue cells in the two types of stains used in this work, we used the "Pearson coefficient". Analyses were performed at 5% statistical significance level.

This study was approved by the Animal Experimentation Ethics Committee of the School of Veterinary Medicine and Zootechnics of Unesp, Botucatu, (Protocol 241/2012).

RESULTS AND DISCUSSION

Of the 50 animals studied, 20 were born eutocia (40%) and the other 30 calves (60%) through mild forced traction (only one person) with the aid of obstetric currents if the amniotic pouch was ruptured for a period longer than 2 hours. All the dystocia observed were of fetal origin: relatively large fetuses in relation to the mother (70%) or with abnormal static (30%), represented by posterior presentation, flexion of the thoracic limbs or neck. One hypothesis that would explain this fact would be that there were, in the experimental period, many calving (primiparous) calves, which are known to have smaller pelvic sizes and higher incidence of dystocia calves (Jainudeen & Hafez 2004).

During labor, disturbances in the uteroplacental blood circulation arise as a result of the contractions of the myometrium, resulting in lower oxygen delivery to the fetus (Walser & Maurer-Schweiser 1979). Thus, in the case of delayed deliveries, this deficiency in fetal oxygenation is greater, predisposing the neonate to more severe degrees of acidosis with consequent decrease in vitality. The logical relationship between dystocia and the impairment of maternal-fetal circulation was the subject of discussion in the study by Massip & Mocsy (1965). The authors concluded that in the case of dystocia calves presented more pronounced acidosis than animals from eutocia calving; yet the greatest impairment came from neonates obtained by emergency cesarean section. However, other authors (Maurer-Schweizer et al. 1977) have shown that calves from spontaneous births and calves with mild traction-assisted births exhibit similar vitality and blood pH characteristics. Due to constant observation of pregnant cows, cases of dystocia were detected early and resolved. Consequently, the experimental animals did not remain in dystocia for a long time and did not develop loss of vitality due to possible acidosis (Table 1). Interestingly, 100% of calves had high vitality, i.e., Apgar score 7 or 8, as this was one of the inclusion criteria in the experiment.

Surfactant synthesis is known to be influenced by pH, body temperature and perfusion and is compromised in acidosis (Bittar 2000). It was already commented in the exclusion criteria that the newborns used in this research presented normal rectal temperature and CPT for the species, according

Table 1. Number of samples (N), means, confidence interval (95% CI), standard error (SE), standard deviation (SD), minimum (Min.) and maximum (Max.) values for blood pH of Black and White Holstein calves and mature, term and healthy at birth: general pH, pH of eutocia animals and pH of animals born by dystocia

Variable	N	Average	IC 95%	EP	DP	Min.	Max.
pH	50	7.22	7.20-7.24	0.01	0.06	6.99	7.34
pH eutocia	20	7.21	7.19-7.23	0.01	0.05	7.1	7.32
pH dystocia	30	7.22	7.20-7.25	0.01	0.07	6.99	7.34

to Feitosa & Benesi (2014), showing good capillary perfusion. There was no statistical difference in the pH of eutocia and dystocia animals ($p=0.44$), which allows them to be considered as a homogeneous group.

Of the 50 samples of amniotic fluid analyzed, 43 (86%) were light colored, five (10%) yellowish and two (4%) reddish. Light color is considered normal in amniotic fluid (Zogno et al. 2004). The yellow color originated from the contamination of the amniotic fluid with the allantoid at the time of collection because a large amount was released moments before the exposure of amnion, leaving part of this fluid in the vaginal canal, although for the types of analysis performed there was no influence on the results. This hypothesis strengthens the fact that no animal was born meconium-dyed by discarding the contamination of amniotic fluid by this substance as a cause of yellowish color. The reddish color occurred due to blood contamination at the time of puncture, which sometimes reached small vessels of the amniotic membrane.

Regarding appearance, all samples were turbid, and 13 of them (26%) also had white lumps. The results of the viscosity classification were distributed as follows: 7 low viscous samples (+/14%), 30 intermediate viscosity samples (+/60%) and 13 very viscous samples (+++/26%). According to the protocol adopted at the School of Medicine of Unesp, Botucatu, where the present study is based, when the amniotic fluid is transparent and without lumps, it indicates pulmonary immaturity, and the cloudy and viscous fluid with lumps should be from mature fetus. However, in calves this relationship was not observed, since all the animals were mature and yet some presented little viscous amniotic fluid or without lumps.

There were no positive samples in the Clements test as originally proposed (Clements et al. 1972), and the same result was obtained after applying the modified Cleto test by Barreto (Barreto et al. 2011), i.e., all amniotic fluid samples were negative. Due to the failure of these two tests, the methodology was adapted again and, from successive attempts with increasing amounts of amniotic fluid, it was found that when mixed 3 mL of amniotic fluid with 1mL of 95% ethanol exclusively, without the addition of physiological solution, the samples formed the complete ring of bubbles, indicating test positivity. After this modification, 100% of the tested liquids were positive, showing parameters of fetal lung maturity in bovine species, since mature animals will have positive test under these dilution conditions. Amniotic fluid samples from premature animals with clinical signs of RDS need to be further tested to confirm that the adapted technique (3mL dilution) will be negative in animals deficient in the amount or quality of surfactant produced. For this, it

would be necessary to adopt the technique of amniocentesis during the final period of pregnancy, since the collection of LA from the slaughterhouse is not effective. It is probably because during the slaughter process, the fetus suffers and contaminates the amniotic fluid with meconium, making the Clements test always false positive, regardless of dilution. This test is particularly interesting because it is a simple technique and applicable to clinical routine, but more studies are needed to establish more precisely the cutoff point for dilution between mature and premature animals.

It was not possible to count the lamellar bodies in the automatic particle counter. Despite successive tests with refrigerated and/or frozen samples, all resulted in close to zero reading. In addition, the device often clogged due to the high viscosity and presence of mucus in the samples. Thus, the transmission electron microscopy was chosen to verify the existence of lamellar bodies in the amniotic fluid of bovine, since there were no studies describing the structure in this species. Castagnetti et al. (2007), evaluating the lung maturity of newborn foals by amniotic fluid analysis by electron microscopy, reported that lamellar bodies were structures composed of several concentric lamellae with a diameter ranging from 1.6 to 3.3 μm , the particle counter methodology being applicable to equine species. After electron microscopy of the amniotic fluid in order to characterize the lamellar bodies of bovine, it was found that these structures are approximately 130nm in diameter (Fig.1). Thus, the morphology of the lamellar bodies of bovine species, still unpublished in the literature, was characterized. As these structures are small, it has been confirmed that their observation by optical microscopy is impossible, proving that the lamellar bodies of the amniotic

fluid of cows are much smaller than those of humans and horses. Therefore, this fact explains the unsuccessful attempts to quantify lamellar bodies by automated particle counters. As the lamellar bodies disintegrate when invoked to cover the surfactant socket, the finding of concentric lamella structures, as described in the literature, was not possible. Thus, for further research the study of these structures still within the pneumocyte is indicated.

Cellularity results with Nile Blue and Hematoxylin-Shorr staining and their proportions and morphologies (Fig.2 and 3) showed no correlation between orangiophilic cell proportions among the different stains studied (Pearson coefficient = -0.14), indicating that the two methodologies do not reflect their results to each other (Tables 2-4). In women, the proportion of orange cells in amniotic fluid during pregnancy is already standardized, representing 50% to 95% of the cell population (Souza et al. 2000). Thus, the high proportion of orangiophilic cells is indicative of fetal maturity. Thereby, the cytology using Nile Blue staining was not satisfactory, since even mature calves presented low percentage of these cells, with an average of 8%. This finding agrees with the results of Moya (2005), who worked with cattle, and Martins & Prestes (2003) in their study with female canine amniotic fluid. In this study, a percentage ten times higher than the one obtained using the Nile Blue staining technique was found, that is, on average 80% of the amniotic fluid cell population of healthy Black and White Holstein calves and the term was composed by orangiophilic cells, which shows that the Hematoxylin-Shorr technique, although more laborious and time consuming, is the most appropriate to predict fetal maturity in the bovine species.




Fig.1. (A-B) Lamellar bodies present in amniotic fluid of the bovine species obtained by the transmission electron microscopy technique. Bar = 100nm.

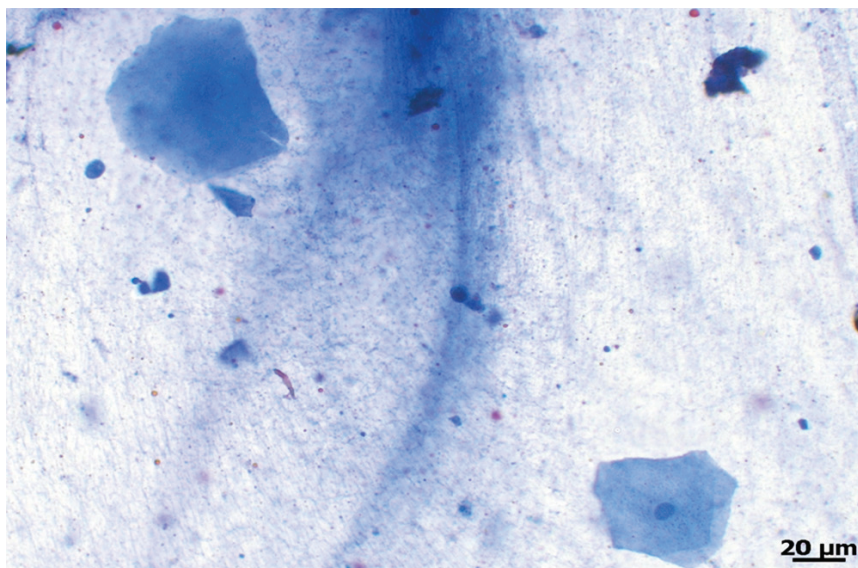


Fig.2. Acidophilic cell morphology (blue cell) obtained by optical microscopy of the cytology of amniotic fluid. Nile Blue, bar = 20μm.

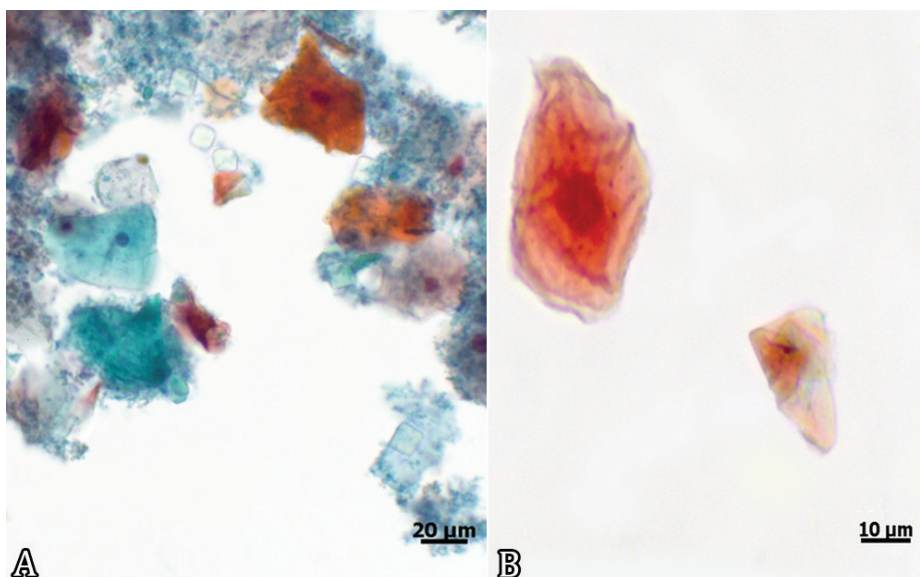


Fig.3. (A-B) Orangophilic cell morphology (orange cell) obtained by optical microscopy of the cytology of the amniotic fluid. Hematoxylin-Shorr; bar = 20μm, bar = 10μm.

Table 2. Number of samples (N), means, confidence intervals (95% CI), standard errors (SE), standard deviations (SD), minimum values (Min.) and maximum values (Max.) for blue and orange cells obtained from amniotic fluid cytology of mature Black and White Holstein calves at term and healthy at calving by Nile Blue staining

Variable	N	Average	IC 95%	EP	DP	Min.	Max.
Blue cells	50	21	16-27	2,7	19	5	103
Orange cells	50	1.7	1.4-2.1	0,18	1.2	1	5

Table 3. Number of samples (N), means, confidence intervals (95% CI), standard errors (SE), standard deviations (SD), minimum values (Min.) and maximum values (Max.) for blue and orange cells obtained from amniotic fluid cytology of mature Black and White Holstein calves at term and healthy at calving using Hematoxylin-Shorr staining

Variable	N	Average	IC 95%	EP	DP	Min.	Max.
Blue cells	50	19	18-21	0.8	5.7	4	28
Orange cells	50	81	79-82	0.8	5.7	28	96

Table 4. Number of samples (N), means, standard deviations (SD), minimum values (Min.) and maximum values (Max.) for proportions between orange and blue cells (O:B) obtained by amniotic fluid cytology of Black and White Holstein calves mature at term and healthy at birth by staining with Nile Blue and Hematoxylin-Shorr

Variable	N	Average	DP	Min.	Max.
O:B Proportion (Nile Blue)	50	8%	2%	4%	16%
O:B Proportion (Hematoxilina-Shorr)	50	80%	5%	72%	96%

CONCLUSIONS

This work found results that characterize the fetal and pulmonary maturity of bovine neonates in the proposed tests, mainly regarding the bovine lamellar body size (approximately 130nm) and the ratio of LA to complete bubble ring formation in the Clements test, 3mL. However, future studies with immature lungs are still needed.

In addition, amniotic fluid cellularity data and surfactant carrier structure morphology, which were previously poorly established for the species, are important for the formation of basic knowledge about fetal maturation. Further studies in this area are needed in different animal species, so that Veterinary Neonatology can match evolution and knowledge with that established in Medicine.

Acknowledgments.- To FMVZ-Unesp/Botucatu, for the physical structure and equipment used to carry out the experiment. To FAPESP (São Paulo State Research Support Foundation) for the Master's Scholarship granted (Process 2012/24836-8).

Conflict of interest statement.- The authors have no competing interests.

REFERENCES

- Barreto C.S., Prestes N.C., Souza F.F., Santos R.V., De Vita B., Matayoshi P.M. & Leal L.S. 2011. Uso do teste de clements modificado e densidade óptica do líquido amniótico e alantoideano para avaliação da maturidade pulmonar em cães. *Vet. Zootec.* 18(1):63-69.
- Benesi F.J. 1993. Síndrome da asfixia neonatal dos bezerros: importância e avaliação crítica. *Arq. Escola Med. Vet. UFBA* 16(1):38-48.
- Bittar R. 2000. Doença das membranas hialinas, p.103-106. In: Rugolo L.M.S.S. (Ed), *Manual de Neonatologia*. 2ª ed. Revinter, Rio de Janeiro.
- Born E. 1981. Untersuchungen über den Einfluss der Schnitttendbindung auf die Vitalität neugeborener Kälber. Dissertation, Tierärztliche Hochschule, Hannover. 47p.
- Campana S.G., Chávez J.H. & Haas P. 2003. Diagnóstico laboratorial do líquido amniótico. *J. Bras. Patol. Med. Lab.* 39(3):215-218.
- Castagnetti C., Mariella J., Serrazanetti G.P., Grandis A., Merlo B., Fabbri M. & Mari G. 2007. Evaluation of lung maturity by amniotic fluid analysis in equine neonate. *Theriogenology* 67(9):1455-1462. <<http://dx.doi.org/10.1016/j.theriogenology.2007.02.013>> <PMid:17448529>

- Clements J.A., Platzker A.C.G., Tierney D.F., Hobel C.J., Creasy R.K., Margolis A.J., Thibeault D.W., Tooley W.H. & Oh W. 1972. Assessment of the risk of the respiratory distress syndrome by a rapid test for surfactant in amniotic fluid. *New England. J. Med.* 286(20):1077-1081. <<http://dx.doi.org/10.1056/NEJM197205182862004>> <PMid:5067186>
- Eigenmann U.E.J., Schoon H.A., Jahn D. & Grunert E. 1984. Neonatal respiratory distress syndrome in the calf. *Vet. Rec.* 114(6):141-144. <<http://dx.doi.org/10.1136/vr.114.6.141>> <PMid:6546630>
- Feitosa F.L.F. & Benesi F.J. 2014. Semiologia de recém-nascidos ruminantes e equídeos, p.69-97. In: *Ibid.* (Eds), *Semiologia Veterinária*. 3ª ed. Roca, São Paulo.
- Gil B.M.K., Souza E., Silva C.A.J. & Figueiredo C.P. 2010. Avaliação da maturidade pulmonar fetal pela contagem dos corpos lamelares no líquido amniótico. *Revta Bras. Ginecol. Obstetr.* 32(3):112-117. <<http://dx.doi.org/10.1590/S0100-72032010000300003>>
- Jainudeen M.R. & Hafez E.S.E. 2004. Gestação, fisiologia pré-natal e parto, p.141-155. In: Hafez B. & Hafez E.S.E. (Eds), *Reprodução Animal*. 7ª ed. Manole, Barueri.
- Martins L.R. & Prestes N.C. 2003. Ensaio sobre exame citológico do líquido amniótico de cadelas colhido no momento da cesariana. *Ars Vet.* 19(3):294-299.
- Massip J. & Mocsy J. 1965. *Tratado de Diagnóstico Clínico de Las Enfermedades Internas de Los Animales Domésticos*. 3ª ed. Labor, Barcelona. 675p.
- Maurer-Schweizer H., Wilhelm U. & Walser K. 1977. Blutgase und Saure-Basenhaushalt bei lebensfrischen Kalbern in den ersten 24 Lebensstunden. *Berliner und Munchener Tierärztliche Wochenschrift* 90(10):192-196. <PMid:883945>
- Moya C.F. 2005. Tipificação citológica do líquido amniótico de bezerros oriundos de produção in vitro, transferência de embrião e inseminação artificial no momento do parto. Master's Thesis, Faculdade de Medicina de Botucatu, Universidade Estadual Paulista, Botucatu, SP. 64p.
- Neerhof M.G., Haney E.I., Silver R.K., Ashwood E.R., Lee I. & Piazze J.J. 2001. Lamellar body counts compared with traditional phospholipids analysis as an assay for evaluating fetal lung maturity. *Obstet. Gynecol.* 97(2):305-309. <PMid:11165600>
- Rebello C.M., Ikegami M., Polk D.H. & Jobe A.H. 1996. Postnatal lung responses and surfactant function after fetal or maternal corticosteroid treatment of preterm lambs. *J. Applied Physiol.* 80(5):1674-1680. <<http://dx.doi.org/10.1152/jappl.1996.80.5.1674>> <PMid:8727554>
- Souza C., Prestes N.C. & Lopes R.S. 2000. Pesquisa de células orangiophilicas e aplicação do teste de Clements no fluido amniótico de ovinos (*Ovis aries*), colhidos em matadouro, em vários estágios da gestação. *Anais XVII Congresso Brasileiro de Medicina Veterinária*, São Paulo, SP, p.29.
- Walser K. & Maurer-Schweizer H. 1979. Acidosis and clinical state in depressed calves, p.551-563. In: Hoffman B., Mason I.L. & Schmidt J. (Eds), *Calving Problems and Early Viability of the Calf. Current Topics in Veterinary Medicine and Animal Science*. Vol.4. Springer Nature, Switzerland.
- Zogno M.A., Miglino M.A. & Oliveira M.F. 2004. Análise bioquímica dos líquidos fetais e citologia do fluido amniótico da fêmea de mocó (*Kerodon rupestris*). *Braz. J. Vet. Res. Anim. Sci.* 41(4):226-235. <<http://dx.doi.org/10.1590/S1413-95962004000400002>>