



## **Post mortem evaluation of spinal cord and protruded intervertebral discs in dogs without neurological abnormalities<sup>1</sup>**

Carolina C. Zani<sup>2</sup>, Paulo V.T. Marinho<sup>3</sup>, Gabriel A.C. Diamante<sup>3</sup>, Felipe A.R. Sueiro<sup>4</sup>  
and Mônica V. Bahr Arias<sup>2\*</sup>

**ABSTRACT.**- Zani C.C., Marinho P.V.T., Diamante G.A.C., Sueiro F.A.R. & Bahr Arias M.V. 2018. **Post mortem evaluation of spinal cord and protruded intervertebral discs in dogs without neurological abnormalities.** *Pesquisa Veterinária Brasileira* 38(9):1793-1799. Departamento de Clínicas Veterinárias, Universidade Estadual de Londrina, Rodovia Celso Garcia Cid Km 380, Londrina, PR 86057-970, Brazil. E-mail: [vicky@uel.br](mailto:vicky@uel.br)

The aim of this study was to verify the presence of protrusion of the intervertebral disc (IVD) causing compression of the spinal cord and/or roots of *cauda equina* in 30 dogs above seven years of age with no evidence of previous neurological abnormalities. After the occurrence of death or euthanasia, a laminectomy was performed from C2 to the sacral vertebra to verify the presence of IVD protrusions. The protruded IVD were macroscopically graded according to the Thompson scale, and the corresponding spinal cord segment was histologically analyzed for nervous tissue compression. Of the 30 dogs, twelve (40%) presented disc protrusion, and of these 12 dogs, seven (58%) presented more than one protruded disc. Disc protrusion was observed in 3.2% (25/780) of all IVD evaluated. Of the six chondrodystrophic dogs, five (83%) presented disc protrusion. Of the 24 nonchondrodystrophic dogs, seven (29%) presented IVD protrusion. The site that showed the highest frequency of protrusion was L4-L5 (6/25) followed by the L6-L7 region (3/25) and C6-C7 (3/25). Only two of the medullary segments evaluated showed histological changes, with presence of focal lymphocytic infiltration and multifocal mild hemorrhage in the gray matter. Under the conditions of this study, 40% of dogs older than seven years old showed IVD protrusions without showing neurological signs, with no abnormality of the nervous tissue in 92% of the evaluated segments. Thus, the protrusion of the IVD in some dogs, can only be a finding of no clinical relevance.

INDEX TERMS: Post mortem, spinal cord, intervertebral disc degeneration, spinal cord, dogs, pathology.

**RESUMO.**- [Avaliação *post mortem* da medula espinhal e de discos intervertebrais protrusos em cães sem alterações neurológicas.] O objetivo do presente estudo foi verificar a presença de protrusão do disco intervertebral (DIV) causando compressão da medula espinhal e/ou raízes da cauda equina em cadáveres de cães, sem histórico de

alterações neurológicas. Para isso, após a ocorrência de óbito ou realização de eutanásia em 30 cães com mais de sete anos de idade, sem histórico de alterações neurológicas, foi realizada a laminectomia entre C2 até a vértebra sacral para verificar a presença de protrusões do DIV. Os DIV protrusos foram graduados macroscopicamente quanto à degeneração segundo a escala de Thompson, e o segmentos medular correspondente à localização da compressão foi analisado microscopicamente em busca de lesões compressivas ao tecido nervoso. Quarenta por cento dos cães (12/30) apresentaram protrusão do DIV, e destes, 58% (7/12) apresentavam mais de um DIV protruso. A protrusão estava presente em 3,2% (25/780) de todos os DIV avaliados. Cães de raças condrodistróficas apresentaram protrusões em 83% dos casos (5/6) e raças não condrodistróficas em 29% (7/24). O local que apresentou maior frequência de protrusão foi L4-L5 (6/25), seguido da

<sup>1</sup> Received on May 28, 2017.

Accepted for publication on October 26, 2017.

<sup>2</sup> Departamento de Clínicas Veterinárias, Universidade Estadual de Londrina (UEL), Rodovia Celso Garcia Cid Km 380, Londrina, PR 86057-970, Brazil.

\*Corresponding author: [vicky@uel.br](mailto:vicky@uel.br)

<sup>3</sup> Departamento de Cirurgia, Faculdade de Medicina Veterinária e Zootecnia, Universidade de São Paulo (USP), Av. Prof. Orlando Marques Paiva 87, Cidade Universitária, São Paulo, SP 05508-900, Brazil.

<sup>4</sup> Laboratório de Patologia e Biologia Molecular Veterinária (Vetpat), Rua Cel. Manuel de Moraes 146, Jardim Brasil, Campinas, SP 13073-022, Brazil.

região L6-L7 (3/25) e C6-C7 (3/25). Apenas dois segmentos medulares avaliados na histopatologia apresentaram alterações, com presença de infiltrado linfoplasmocitário focal e hemorragia discreta multifocal na substância cinzenta. Nas condições do presente estudo, 40% dos cães com mais de sete anos de idade apresentaram protrusões do DIV sem que houvesse sinais neurológicos, com normalidade do tecido nervoso em 92% dos segmentos avaliados. Assim, a protrusão do DIV, em alguns cães, pode ser apenas um achado sem relevância clínica.

TERMOS DE INDEXAÇÃO: *Post mortem*, medula espinhal, degeneração do disco intervertebral, medula espinhal, cães, patologia.

## INTRODUCTION

Intervertebral disc degeneration (IVDD) is a common consequence of aging resulting in progressive pathological changes in structure, biomechanics and function of the disc (Bergknut et al. 2013, Jeffery et al. 2013). The changes mainly occur in the composition of the cells and extracellular matrix (Bergknut et al. 2013). Disc degeneration is traditionally classified as Hansen type I (nuclear extrusion) or Hansen type II (nuclear protrusion) (Hansen 1952). Hansen type I disc disease is a well-established condition in chondrodystrophic dogs (Hansen 1952, Brisson 2010, Jeffery et al. 2013) that has also been described in large dogs (Macias et al. 2002).

In type I degeneration, the degenerated nucleus of the disc can acutely extrude through the ruptured dorsal annulus, causing spinal cord compression and resulting in a mixed compressive and contusive lesion of the spinal cord (Jeffery et al. 2013). Type II degeneration tends to occur mainly in nonchondrodystrophic dogs, following fibroid metaplasia. The nucleus pulposus is gradually replaced by collagenous tissue and simultaneous degeneration of the annulus fibrosus, resulting in loosening and fragmentation of the lamellae (Downes et al. 2009) and annular hypertrophy (Jeffery et al. 2013). These tend to occur gradually with dorsal bulging of the disc causing progressive spinal cord compression, whose effects are most prevalent in the white matter and result in chronic spinal cord compression that can cause cord atrophy (Downes et al. 2009, Jeffery et al. 2013, De Decker et al. 2016). Annular protrusions usually affect large, nonchondrodystrophic dogs with the German shepherd dog the most commonly affected breed that represents more than half of all cases (Macias et al. 2002).

There is no standardization in the nomenclature of these disorders, particularly in the differentiation among disc degeneration, disc disease, disc displacement, extrusion and protrusion (Fingerroth & Thomas 2015). Differentiating these subtypes of intervertebral disc degeneration may impact treatment recommendations and outcomes (Fingerroth & Thomas 2015, De Decker et al. 2016) and allow a better comparison among treatment results. This is important because in comparison with type I intervertebral disc disease, there are far fewer studies about type II disc disease (Cudia & Duval 1997, Macias et al. 2002, Moissonnier et al. 2004, Gaitero & Añor 2009, Schmied et al. 2011). In other studies, the term protrusion or herniation is used instead of extrusion, making it difficult to assess the real meaning of type II degeneration in dogs and the results of treatments described in literature (Kinzel et al. 2005, Flegel et al. 2011, De Decker et al. 2016).

Another problem related to type II disc degeneration is the lower effectiveness of surgical treatment when compared to results of surgical treatment for Type I disc disease. Many dogs presented a temporary or definitive worsening after surgical treatment that can include many techniques, such as standard hemilaminectomy with or without annulectomy of protruded material, hemilaminectomy combined with vertebral plate stabilization, dorsal laminectomy, ventral slot and lateral corpectomy (McKee & Downes 2008, Moissonnier et al. 2004, Downes et al. 2009, Cherrone et al. 2004, Gaitero & Añor 2009, Ferrand et al. 2015), raising the question as to whether these dogs could have disc degeneration and annular protrusion as a response to aging. Therefore, the purpose of this study was to analyze the frequency of disc degeneration in cadaveric spines of dogs older than seven years old without a history of neurological disease.

## MATERIALS AND METHODS

The carcasses of 30 dogs older than seven years of age euthanatized for reasons unrelated to this study were obtained as approved by the institution's animal care and use committee (no. 155/2013). None of the dogs had a history of neurological disease. The specimens were harvested within one hour of death.

After the death or euthanasia, a dorsal laminectomy was performed between the second cervical vertebra (C2) and the sacral vertebra. The spinal cord and cauda equina were inspected to find compression by disc protrusion and then carefully removed. The floor of the vertebral canal was evaluated for the presence of disc protrusion. The spines were transected in the midsagittal plane with an oscillating saw and then the adjacent endplates and protruded IVD were removed from the adjacent vertebral bodies and were used for grading according to the Thompson scheme that evaluate pathological changes of the nucleus pulposus, annulus fibrosus, end plates, and periphery of the vertebral body (Bergknut et al. 2011). The corresponding spinal cord segments were fixed in formalin (10%). After fixation in formalin, the tissues were embedded in paraffin, sectioned transversely into 5µm sections, stained with hematoxylin-eosin (HE) and assessed by light microscopy. For each IVD with protrusion, the corresponding spinal segment was evaluated, thus verifying the presence of histological changes due to chronic spinal cord compression.

The total number of dogs that exhibited disc protrusions and the number of affected IVD were compared to the total number of dogs and to the total number of IVD studied, respectively. To facilitate interpretation, the IVD were further grouped into macro regions, established in the literature (De Lahunta et al. 2015) for presenting the same neurological syndromes, including the cervical (C1-C5 spinal cord segments, C1-C4 vertebrae) cervicothoracic (C6-T2 spinal cord segments, C5-T1 vertebrae), thoracolumbar (T3-L3 spinal cord segments, T2-L3 vertebrae) and lumbosacral regions (L4-S3 spinal cord segments and cauda equina, L4-S1 vertebrae). The chi-square test, at a significance level of 5%, was used to verify the occurrence of differences in the number of protrusions in the macro regions. All statistical analyses were performed with R-R version 3.1.1 program.

## RESULTS

The ages of the dogs ranged from 7 to 17 years old (mean age 10,7 years old, median age 10 years old). Six dogs were chondrodystrophic dogs, and 24 were nonchondrodystrophic

dogs. Fifteen dogs were females and 15 were males, weighing 6 to 36 kg (mean 15.15 kg, median 12.9 kg) (Table 1).

In each spine, 26 IVDs were evaluated for a total of 780 IVDs. IVD protrusion was observed in 40% (12/30) of dogs (Table 1; Fig.1A), with 25/780 (3.2%) protruded discs. In 58% (7/12) of dogs that presented with IVD protrusion, there was involvement of more than one intervertebral disc with five as the maximum number of protruded discs in one dog

IVD protrusion more frequently affected the L4-L5 region (dogs 3, 4, 8, 13, 24 and 25), followed by L6-L7 (dogs 3, 4 and 17) and C6-C7 (dogs 9, 12 and 13). The distribution between nonchondrodystrophic and chondrodystrophic dogs is shown in Figure 1B and 1C respectively. IVD protrusion was observed in 83% of the chondrodystrophic dogs (dogs 8,9,12,18,24), whereas IVD protrusion was present in 29% of the nonchondrodystrophic dogs (dogs 1,3,4,13,17,20,25).

**Table 1. Characteristics of the sample population of dogs without neurological signs, according to breed, bone growth type, age, weight, localization of protruded intervertebral disc and macroscopic grade of disc degeneration**

Dog	Breed	Bone growth type	Age (years)	Weight (kg)	Localization of protruded disc	Macroscopic classification of IVD (Thompson scheme)
1	Akita	NC	12	36	T13-L1 L3-L4	III V
2	English Cocker Spaniel	C	14	16	-	-
3	MB	NC	14	13	L4-L5 L6-L7 L7-S1	III III V
4	MB	NC	17	21,6	T2-T3 T12-T13 L4-L5 L5-L6 L6-L7	IV III II II III
5	MB	NC	8	11	-	-
6	MB	NC	10	10	-	-
7	MB	NC	13	12,8	-	-
8	Poodle	C	17	7	L1-L2 L2-L3 L4-L5 L5-L6	III III III III
9	Poodle	C	10	9,3	C6-C7	IV
10	MB	NC	7	16	-	-
11	MB	NC	8	10	-	-
12	Dachshund	C	13	10	C5-C6 C6-C7	IV IV
13	MB	NC	10	7,4	C6-C7 L4-L5	V III
14	MB	NC	12	15,5	-	-
15	MB	NC	7	12	-	-
16	German Shepherd	NC	8	23	-	-
17	Boxer	NC	7	27	C7-T1 L6-L7	III III
18	Poodle	C	13	6	L1-L2	III
19	MB	NC	7	14	-	-
20	MB	NC	11	11	L7-S1	V
21	MB	NC	10	11	-	-
22	MB	NC	9	14	-	-
23	Pitbull	NC	10	22	-	-
24	Dachshund	C	11	12	L4-L5	III
25	MB	NC	13	10	L4-L5	II
26	MB	NC	8	11	-	-
27	Pitbull	NC	7	20	-	-
28	MB	NC	8	15	-	-
29	MB	NC	16	16	-	-
30	Boxer	NC	11	35	-	-

C = chondrodystrophic dogs, NC = nonchondrodystrophic dogs, MB = mixed breed dog.

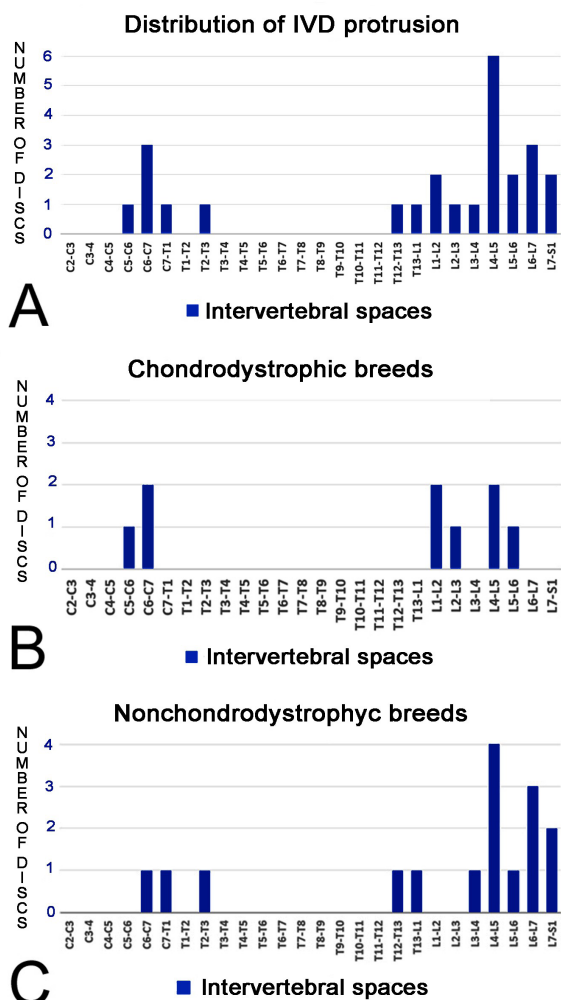


Fig.1. (A) Frequency of protruded intervertebral discs for all 30 dogs. (B) Frequency of protruded intervertebral discs in chondrodystrophic dogs. (C) Frequency of protruded intervertebral discs in nonchondrodystrophic dogs.

By grouping protrusions into macro regions, it was observed that disc protrusions did not occur in the cervical region. A total of 6/25 (24%; dogs 9,12,13,17) protruded discs were observed in the cervicothoracic region, 5/25 (20%; dogs 1,4,8,18) in the thoracolumbar region and 14/25 (56%; dogs 3,4,8,13,17,20,24,25) in the lumbosacral region. A significant difference with regard the number of disc protrusions among vertebral regions was observed ( $P < 0,001$ ); however, when only the affected regions were compared, the differences among these regions were not significant ( $P = 0,053$ ).

By using the macroscopic grading scheme for gross pathological changes in intervertebral discs according to Thompson scheme (Bergknut et al. 2011), it was observed that grade III was the most frequent (14/25), followed by grade IV and V (4/25 each grade) and II (3/25) (Table 1).

In the histopathological evaluation of the spinal cord segments and/or nerve roots corresponding to the intervertebral spaces with disc protrusion, it was found that only 2 segments (8%) had changes. A segment (L2-L3, dog 8) presented

multifocal areas of mild hemorrhage in the gray matter, and the second segment (L6-L7, dog 17) revealed evidence of focal lymphocytic infiltration.

### DISCUSSION

This study demonstrated that almost half of medium-sized dogs without neurological signs, older than seven years old presented IVD degeneration. Disc degeneration is a normal process that occurs with aging, but in some cases can result in diseases, due to disc herniation and spinal cord and nerve root compression. In many cases IVD degeneration may be associated with lumbosacral stenosis and cervical spondylomyelopathy (De Lahunta et al. 2015). Although the process of degeneration is extremely common, especially in chondrodystrophic breeds, many affected dogs exhibit no clinical signs of this degenerative process (Jeffery et al. 2013), as observed in the present study, being necessary to differentiate disc disease from disc degeneration.

Others authors have also reported similar findings. In a study using low-field magnetic resonance imaging (MRI) in 37 clinically normal dogs, severe MRI abnormalities were detected in 17 dogs, including complete disc degeneration in four dogs, spinal cord compression in three and both conditions in ten. The severity of disc degeneration and spinal cord compression was significantly associated with increased age (De Decker et al. 2010). In another study, the morphologic and morphometric features of the cervical vertebral column and spinal cord of Doberman Pinschers with and without clinical signs of cervical spondylomyelopathy were compared via magnetic resonance imaging (MRI). A high percentage of clinically normal Doberman Pinschers had severe abnormalities in the cervical vertebral column, such as spinal cord compression, intervertebral disc degeneration or protrusion, and foraminal stenosis. Among 16 clinically normal dogs, 12 had disc degeneration, and multiple discs were affected in 11 dogs (da Costa et al. 2006), as seen in the present study. As the presence of degenerated IVD was an incidental finding in dogs without clinical signs of spinal cord disease, it was recommended by Jones et al. (2005) and da Costa et al. (2006) to be careful when attributing clinical importance to these changes. The same was observed in human patients: in MRI images from the cervical regions of 1211 healthy human beings, 87.6% presented disc bulging. The presence of this alteration increased with age, particularly after 50 years, and according to the author, the results highlight the fact that clinical decision making should be prudent, correlating MRI findings with clinical signs and symptoms (Nakashima et al. 2015).

In the present study IVD protrusion or type II hernias were found more frequently in thoracolumbar, lumbar and cervical caudal spine (C5-T1). Our findings were similar to those reported by other authors (Hansen 1952, Cudia & Duval 1997, Macias et al. 2002, Brisson 2010, Meij & Bergknut 2010, Jeffery et al. 2013) that noticed that type II hernias are found mostly in the cervical caudal spine, thoracolumbar junction and L7-S1 discs. In another study comparing the severity of IVD herniation using MRI and disc histopathology in 74 surgically treated dogs, type II hernias were found mostly in the lumbosacral segment and less frequently in the cervical and thoracolumbar regions (Kranenburg et al. 2013). In our study, the thoracolumbar spine, mainly between T12-L2, was



the second most commonly affected region. It is important to consider this when dealing with dogs with neurological signs compatible with thoracolumbar or lumbosacral syndrome, because there are other disorders to be considered in the differential diagnosis in these spinal cord segments, such as inflammatory and infectious diseases, fibrocartilaginous embolic myelopathy, degenerative myelopathy, neoplasia and diskospondylitis (De Lahunta et al. 2015), even if there are changes in the imaging tests, suggesting IVD degeneration with spinal cord compression. In a study with eight large-breed dogs with clinical diagnoses of degenerative myelopathy, CT myelography was performed, and in all dogs morphologic abnormalities of the spine were observed, including disc protrusions in 21/32 discs examined (Jones et al. 2005).

The presence of multiple protrusions found in 58% of dogs with IVD protrusion in the present study was reported in another study, mainly in the thoracic region of German Shepherd dogs, and interestingly, the authors concluded that in the majority of the dogs the site of compression did not coincide with the site of neurological localization (Gaitero et al. 2013). In another study with 723 dogs with IVD degeneration diagnosed by MRI, large-breed dogs were more likely to have multiple regions affected mainly in the T1-T9 region (Hearon et al. 2014). The management of multiple protrusions is challenging, and it is a concern if all protrusions play a role in the development of clinical signs. The presence of multiple intervertebral disc herniation was the variable with the highest intraobserver agreement for the diagnosis of disc protrusion, in a study using guidelines to assist in the differentiation between disc extrusion and protrusion in large breeds (De Decker et al. 2016). Triple thoracolumbar disc protrusions, or simultaneous protrusion in three discs, causing moderate to severe spinal cord compression were diagnosed by RM in two German Shepherd dogs, which were managed by decompression and vertebral stabilization. Despite improvement of spinal pain and ataxia, neurological deficits persisted (McKee & Downes 2008). In these dogs, CSF examination was not performed to rule out other diseases, reinforcing our hypothesis that maybe disc protrusion was incidental and another disease was responsible by the neurological signs.

In the present study, all stages of the degenerative process were identified in the IVD, both in chondrodystrophic and nonchondrodystrophic dogs, being grade III the most frequent. According to the Thomson scheme that has been validated for use in dogs (Bergknut et al. 2011), IVD degeneration can be divided into five stages, ranging from a healthy IVD (grade I) to a severely degenerated IVD (grade V). This scheme proved to be a reliable method for macroscopic grading disc degeneration scores, and in dogs it had substantial agreement with low-field MRI findings graded according to the Pfirrmann system in humans (Bergknut et al. 2011). As observed in the present study and by other authors (Seiler et al. 2003, Kranenburg et al. 2013), the grade of IVD degeneration is not correlated with clinical signs. Seiler et al. (2003), used histopathology and magnetic resonance to study 33 intervertebral discs from the caudal lumbar spine (L5-S1) of 11 large-breed dogs weighing between 25 and 40 kg and between 10 months and 8 years of age selected randomly at necropsy, and found that eight discs presented degeneration, concluding that MR imaging can be used to reliably detect and classify degenerative

changes in caudal lumbar intervertebral discs, however, no clinical history of the dogs was available to correlate IVD degeneration and clinical signs.

Although in the classic study of Hansen (1952) about disc degeneration it was suggested that disc protrusions occur most commonly in nonchondrodystrophic breeds of dogs, this was not verified in the present study, confirming what was observed by Smolders et al. (2013), who demonstrated by histology that the degeneration of the IVD in chondrodystrophic and nonchondrodystrophic dogs is much more similar than it was proposed. However, there are no studies with large numbers of chondrodystrophic dogs affected only by type II disc degeneration. Type I intervertebral disc disease is extensively more common and more studied, tends to produce an acute syndrome and the rate of success of surgical treatment is better than for type II disc disease. This discrepancy is probably due to the chronicity of spinal cord compression or excessive spinal cord manipulation during surgery in type II disc disease (Moissonnier et al. 2004, Gaitero & Añor 2009), but even performing corpectomy, a new surgical technique developed to decrease spinal cord manipulation during surgery, worsening of neurological status occurred in some dogs with IVD degeneration type II (Ferrand et al. 2015), raising the question that these dogs could have disc degeneration and annular protrusion as a response to aging. In addition, the unsuccessful results of treatment in some dogs may be due to the presence of another neurological disease not properly investigated.

The results of spinal cord histology corroborate the above statement, as in our study, 92% (23/25) of compressed spinal cord segments evaluated did not present histological alterations. Although it is proposed that chronic spinal cord compression due to annular protrusion causes chronic compressive spinal cord injury, this was not observed in the present study, and there are few studies on this particular point (Jeffery et al. 2013). In this type of injury, it is theorized that the dynamic force is low, and the spinal cord adapts using compensatory mechanisms (Toombs & Waters 2007, Jeffery et al. 2013). It is proposed that axonal loss occurs with evidence of Wallerian degeneration, with a predominance of the lesions in the white matter, possibly due to low blood flow as a result of the compression (Jeffery et al. 2013). In other studies, it was found that the epicenter of spinal cord injuries occurs in the peripheral areas of gray matter, affecting both gray and white matter (Kato et al. 1985, Al-Mefty et al. 1993, Uchida et al. 1998), however none of these findings were seen in the present study.

One spinal cord segment (dog 8, L2-L3) presented mild multifocal hemorrhage in the gray matter. The etiologies for the occurrence of multifocal hemorrhages in the spinal cord are traumatic injury, inflammatory, and vascular or neoplastic events (Vandeveldt et al. 2012). The vascular or neoplastic causes had been ruled out due to the absence of emboli and atypical cells, respectively. As the dog did not show neurological signs, it is believed that the changes have resulted from failure of tissue handling during collection or processing. The second spinal cord segment (dog 17, L6-L7), presented a focal lymphoplasmacytic inflammatory infiltrate. This pattern is observed in nonsuppurative inflammations, especially those caused by viral infections (Vandeveldt et al. 2012). As this dog was euthanized due to the presence of neoplasia, it is

assumed that comorbidities such as viral infections could be present but were not causing clinical signs or were not causing evident neurological signs at the time of evaluation.

Limitations of this study include the lack of realization of complete neurological examination due to the presence of other debilitating conditions that led to the death or euthanasia of patients and the small number of chondrodystrophic dogs studied in relation to the number of nonchondrodystrophic dogs. Despite this, as found in the present paper and noted by other authors, disc degeneration can be an incidental finding in dogs with and without clinical signs of disease (Hansen 1952, Da Costa et al. 2006, De Decker et al. 2010). As highlighted in a recent study, reaching an accurate diagnosis and differentiation between extrusion and protrusion is very important for surgical planning and prognosis (De Decker et al. 2016). Thus, the clinician must be careful when dealing with a dog with spinal neurological signs and disc protrusion. Other possible causes for the clinical signs should be considered to avoid performing a surgical procedure unnecessarily.

## CONCLUSIONS

In this study, 40% over 7 years old dogs showed intervertebral disc (IVD) protrusion, and of these, 58% had multiple protrusions not associated with histopathological alterations in spinal cord.

It can be suggested that disc protrusions are not necessarily associated with the development of neurological signs in dogs older than seven years of age, and thus, considerations should be given in dogs in this age group for the possibility that the radiographic studies or advanced imaging findings of herniated disc are not causing the neurological signs, thus avoiding erroneous diagnosis and treatment.

In dogs with neurological signs and alterations in imaging tests compatible with disc degeneration is important to consider the possibility of asymptomatic degenerated discs.

**Conflict of interest statement.**- The authors have no conflicts of interest.

**Acknowledgements.**- The authors are grateful to Laboratório de Patologia e Biologia Molecular Veterinária (Vetpat) for carrying out the histopathological analysis, to the Coordination of Improvement of Higher Personnel Education (Coordenação de Aperfeiçoamento de Pessoal de Nível Superior - CAPES) for granting a master's scholarship to Carolina Camargo Zani, and to CNPq and Institutional Scientific Initiation Scholarship Program PIBIC/UEL for granting a Scientific Initiation Scholarship to Marina Bueno Santoro and Geovane José Pereira, who collaborated in collecting data.

## REFERENCES

Al-Mefty O., Harkey H.L., Marawi I., Haines D.E., Peeler D.F., Wilner H.I., Smith R.R., Holaday H.R., Haining J.L., Russell W.F., Harrison B. & Middleton T.H. 1993. Experimental chronic compressive cervical myelopathy. *J. Neurosurg.* 79(4):550-561. <<http://dx.doi.org/10.3171/jns.1993.79.4.0550>> <PMid:8410225>

Bergknut N., Grinwis G., Pickee E., Auriemma E., Lagerstedt A.S., Hagman R., Hazewinkel H.A. & Meij B.P. 2011. Reliability of macroscopic grading of intervertebral disc degeneration in dogs by use of the Thompson system and comparison with low-field magnetic resonance imaging findings. *Am. J. Vet. Res.* 72(7):899-904. <<http://dx.doi.org/10.2460/ajvr.72.7.899>> <PMid:21728850>

Bergknut N., Smolders L.A., Grinwis G.C., Hagman R., Lagerstedt A.S., Hazewinkel H.A., Tryfonidou M.A. & Meij B.P. 2013. Intervertebral disc degeneration

in the dog. part 1: anatomy and physiology of the intervertebral disc and characteristics of intervertebral disc degeneration. *Vet. J.* 195(3):282-291. <<http://dx.doi.org/10.1016/j.tvjl.2012.10.024>> <PMid:23177522>

Brisson B.A. 2010. Intervertebral disc disease in dogs. *Vet. Clin. N. Am., Small Anim. Pract.* 40(5):829-858. <<http://dx.doi.org/10.1016/j.cvs.2010.06.001>> <PMid:20732594>

Cherrone K.L., Dewey C.W., Coates J.R. & Bergman R.L. 2004. A retrospective comparison of cervical intervertebral disc disease in nonchondrodystrophic large dogs versus small dogs. *J. Am. Anim. Hosp. Assoc.* 40(4):316-320. <<http://dx.doi.org/10.5326/0400316>> <PMid:15238562>

Cudia S.P. & Duval J.M. 1997. Thoracolumbar intervertebral disc disease in large, nonchondrodystrophic dogs: a retrospective study. *J. Am. Anim. Hosp. Assoc.* 33(5):456-460. <<http://dx.doi.org/10.5326/15473317-33-5-456>> <PMid:9278123>

Da Costa R.C., Parent J.M., Partlow G., Dobson H., Holmberg D.L. & Lamarre J. 2006. Morphologic and morphometric magnetic resonance imaging features of Doberman Pinschers with and without clinical signs of cervical spondylomyelopathy. *Am. J. Vet. Res.* 67(9):1601-1612. <<http://dx.doi.org/10.2460/ajvr.67.9.1601>> <PMid:16948609>

De Decker S., Gielen I.M., Duchateau L., Van Soens I., Bavegems V., Bosmans T., Van Bree H.J. & Van Ham L.M. 2010. Low-field magnetic resonance imaging findings of the caudal portion of the cervical region in clinically normal doberman pinschers and foxhounds. *Am. J. Vet. Res.* 71(4):428-434. <<http://dx.doi.org/10.2460/ajvr.71.4.428>> <PMid:20367050>

De Decker S., Gomes S.A., Packer R.M., Kenny P.J., Beltran E., Parzefall B., Fenn J., Nair D., Nye G. & Volk H.A. 2016. Evaluation of magnetic resonance imaging guidelines for differentiation between thoracolumbar intervertebral disk extrusions and intervertebral disk protrusions in dogs. *Vet. Radiol. Ultrasound* 57(5):526-533. <<http://dx.doi.org/10.1111/vru.12394>> <PMid:27374979>

De Lahunta A., Glass E. & Kent M. 2015. Small animal spinal cord disease, p.257-303. In: De Lahunta A., Glass E. & Kent M. (Eds), *Veterinary Neuroanatomy and Clinical Neurology*. 4th ed. W.B. Saunders, Philadelphia.

Downes C.J., Gemmill T.J., Gibbons S.E. & McKee W.M. 2009. Hemilaminectomy and vertebral stabilisation for the treatment of thoracolumbar disc protrusion in 28 dogs. *J. Small Anim. Pract.* 50(10):525-535. <<http://dx.doi.org/10.1111/j.1748-5827.2009.00808.x>> <PMid:19796311>

Ferrand F.X., Moissonnier P., Filleur A., Cachon T., Fau D., Viguier E. & Carozzo C. 2015. Thoracolumbar partial lateral corpectomy for the treatment of chronic intervertebral disc disease in 107 dogs. *Ir. Vet. J.* 68(1):27. <<http://dx.doi.org/10.1186/s13620-015-0056-z>> <PMid:26629329>

Fingerroth J.M. & Thomas W.B. 2015. *Advances in Intervertebral Disc Disease in Dogs and Cats*. Wiley-Blackwell, Ames, Iowa. 344p. <<http://dx.doi.org/10.1002/9781118940372>>.

Flegel T., Boettcher I.C., Ludewig E., Kiefer I., Oechtering G. & Böttcher P. 2011. Partial lateral corpectomy of the thoracolumbar spine in 51 dogs: assessment of slot morphometry and spinal cord decompression. *Vet. Surg.* 40(1):14-21. <<http://dx.doi.org/10.1111/j.1532-950X.2010.00747.x>> <PMid:21077918>

Gaitero L. & Añor S. 2009. Cranial thoracic disc protrusions in three german shepherd dogs. *Vet. J.* 182(2):349-351. <<http://dx.doi.org/10.1016/j.tvjl.2008.06.018>> <PMid:18691916>

Gaitero L., Nykamp S., Daniel R. & Monteith R. 2013. Comparison between cranial thoracic intervertebral disc herniations in german shepherd dogs and other large breed dogs. *Vet. Radiol. Ultrasound* 54(2):133-138. <<http://dx.doi.org/10.1111/vru.12005>> <PMid:23278950>

Hansen H.J. 1952. A pathologic-anatomical study on disc degeneration in dog, with special reference to the so-called enchondrosis intervertebralis. *Acta Orthop. Scand.* 11(Suppl.11):1-117. <<http://dx.doi.org/10.3109/ort.1952.23.suppl-11.01>> <PMid:14923291>

- Hearon K, Berg J.M., Bonczynski J.J., Suarez C. & Bergman P. 2014. Upper thoracic disc disease (T1-T9) in large-breed dogs. *J. Am. Anim. Hosp. Assoc.* 50(2):105-111. <<http://dx.doi.org/10.5326/JAAHA-MS-5990>> <PMid:24446398>
- Jeffery N.D., Levine J.M., Olby N.J. & Stein V.M. 2013. Intervertebral disk degeneration in dogs: consequences, diagnosis, treatment, and future directions. *J. Vet. Intern. Med.* 27(6):1318-1333. <<http://dx.doi.org/10.1111/jvim.12183>> <PMid:24010573>
- Jones J.C., Inzana K.D., Rossmesl J.H., Bergman R.L., Wells T. & Butler K. 2005. CT Myelography of the thoraco-lumbar spine in 8 dogs with degenerative myelopathy. *J. Vet. Sci.* 6(4):341-348. <PMid:16293999>
- Kato A., Ushio Y., Hayakawa T., Yamada K., Ikeda H. & Mogami H. 1985. Circulatory disturbance of the spinal cord with epidural neoplasm in rats. *J. Neurosurg.* 63(2):260-265. <<http://dx.doi.org/10.3171/jns.1985.63.2.0260>> <PMid:3926963>
- Kinzel S., Wolff M., Buecker A., Krombach G.A., Stopinski T., Afify M., Weiss C. & Kupper W. 2005. Partial percutaneous discectomy for treatment of thoracolumbar disc protrusion: retrospective study of 331 dogs. *J. Small Anim. Pract.* 46(10):479-484. <https://doi.org/10.1111/j.1748-5827.2005.tb00276.x>. PMID: 16245661.
- Kranenburg H.J., Grinwis G.C., Bergknot N., Gahrman N., Voorhout G., Hazewinkel H.A. & Meij B.P. 2013. Intervertebral disc disease in dogs. 2. Comparison of clinical, magnetic resonance imaging, and histological findings in 74 surgically treated dogs. *Vet. J.* 195(2):164-171. <<http://dx.doi.org/10.1016/j.tvjl.2012.06.001>> <PMid:22795604>
- Macias C., McKee W.M., May C. & Innes J.F. 2002. Thoracolumbar disc disease in large dogs: a study of 99 cases. *J. Small Anim. Pract.* 43(10):439-446. <<http://dx.doi.org/10.1111/j.1748-5827.2002.tb00010.x>> <PMid:12400641>
- McKee W.M. & Downes C.J. 2008. Vertebral stabilisation and selective decompression for the management of triple thoracolumbar disc protrusions. *J. Small Anim. Pract.* 49(10):536-539. <<http://dx.doi.org/10.1111/j.1748-5827.2008.00582.x>> <PMid:18631222>
- Meij B.P. & Bergknot N. 2010. Degenerative lumbosacral stenosis in dogs. *Vet. Clin. N. Am., Small Anim. Pract.* 40(5):983-1009. <<http://dx.doi.org/10.1016/j.cvsm.2010.05.006>> <PMid:20732601>
- Moissonnier P., Meheust P. & Carozzo C. 2004. Thoracolumbar lateral corpectomy for treatment of chronic disk herniation: technique description and use in 15 dogs. *Vet. Surg.* 33(6):620-628. <<http://dx.doi.org/10.1111/j.1532-950X.2004.04085.x>> <PMid:15659018>
- Nakashima H., Yukawa Y., Suda K., Yamagata M., Ueta T. & Kato F. 2015. Abnormal findings on magnetic resonance images of the cervical spines in 1211 asymptomatic subjects. *Spine* 40(6):392-398. <<http://dx.doi.org/10.1097/BRS.0000000000000775>> <PMid:25584950>
- Schmid O., Golini L. & Steffen F. 2011. Effectiveness of cervical hemilaminectomy in canine Hansen type I and type II disc disease: a retrospective study. *J. Am. Anim. Hosp. Assoc.* 47(5):342-350. <<http://dx.doi.org/10.5326/JAAHA-MS-5604>> <PMid:21852506>
- Seiler G., Häni H., Scheidegger J., Busato A. & Lang J. 2003. Staging of lumbar intervertebral disc degeneration in nonchondrodystrophic dogs using low-field magnetic resonance imaging. *Vet. Radiol. Ultrasound* 44(2):179-184. <<http://dx.doi.org/10.1111/j.1740-8261.2003.tb01268.x>> <PMid:12718353>
- Smolders L.A., Bergknot N., Grinwis G.C., Hagman R., Lagerstedt A.S., Hazewinkel H.A., Tryfonidou M.A. & Meij B.P. 2013. Intervertebral disc degeneration in the dog. 2. Chondrodystrophic and nonchondrodystrophic breeds. *Vet. J.* 195(3):292-299. <<http://dx.doi.org/10.1016/j.tvjl.2012.10.011>> <PMid:23154070>
- Toombs J.P. & Waters D.J. 2007. Intervertebral disc disease, p.1193-1208. In: Slatter D. (Ed.), *Textbook of Small Animal Surgery*. 3rd ed. Elsevier, Philadelphia.
- Uchida K., Baba H., Maezawa Y., Furukawa S., Furusawa N. & Imura S. 1998. Histological investigation of spinal cord lesions in the spinal hyperostotic mouse (twy/twy): morphological changes in anterior horn cells and immunoreactivity to neurotropic factors. *J. Neurol.* 245(12):781-793. <<http://dx.doi.org/10.1007/s004150050287>> <PMid:9840350>
- Vandeveldel M., Higgins R. & Oevermann A. 2012. *Veterinary Neuropathology: Essentials of Theory and Practice*. Wiley-Blackwell, Ames, Iowa. 210p.