

Acetabular deepening in the treatment of severe canine hip dysplasia¹

Paulo Iamaguti², Luciana S. Iamaguti² and Raquel Sartor^{3*}

ABSTRACT.- Iamaguti P., Iamaguti L.S. & Sartor R. 2009. **Acetabular deepening in the treatment of severe canine hip dysplasia.** *Pesquisa Veterinária Brasileira* 29(2):163-166. Departamento de Reprodução Animal e Radiologia Veterinária, Faculdade de Medicina Veterinária e Zootecnia, Universidade Estadual Paulista, Distrito de Rubião Júnior s/n, Botucatu, SP 18618-000, Brazil. E-mail: raquelsartor@yahoo.com.br

A technique to restore acetabular anatomy by deepening the acetabular cavity and reconstructing the femoral head ligament and the joint capsule was tested on nine large breed dogs with severe hip dysplasia and acute subdislocation or dislocation. The technique consisted of two phases. First, all dogs were submitted to bilateral pectinotomy. In a second surgical intervention on the same dogs the acetabulum was approached and deepened, and the femoral head ligament and the joint capsule were reconstructed. In general, within 30 days of the surgery dogs could stand on the operated member to walk. Except for two dogs, all the others recovered pelvic member locomotive ability within 60-90 days after surgery. It is concluded that acetabuloplasty is a good alternative for treatment of severe canine hip dysplasia.

INDEX TERMS: Diseases of dogs, surgery, hip dysplasia, acetabuloplasty.

RESUMO.- [Aprofundamento do acetábulo no tratamento de displasia coxofemoral grave em cães.] Uma técnica para restituir a anatomia acetabular com aprofundamento da cavidade acetabular e reconstrução do ligamento da cabeça do fêmur e da cápsula articular, foi testada em nove cães, de raças de grande porte, portadores de displasia coxofemoral grave com subluxação acentuada ou luxação. O procedimento cirúrgico foi constituído de duas fases. Inicialmente, foi realizada a pectineotomia bilateral em todos os cães. A segunda intervenção nos mesmos cães incluiu abordagem e aprofundamento do acetábulo, reconstrução do ligamento da cabeça do fêmur e da cápsula. Em geral, 30 dias após a cirurgia, os cães apoiavam o membro operado para se locomover. Com exceção de dois cães, todos os outros recuperaram a fun-

ção locomotora do membro pélvico dentro de 60-90 dias. É concluído que a técnica de acetabuloplastia é uma boa alternativa para o tratamento da displasia coxofemoral grave.

TERMOS DE INDEXAÇÃO: Doenças de cães, cirurgia, displasia coxofemoral, acetabuloplastia.

INTRODUCTION

Hip dysplasia (HD) is the abnormal development of the hip joint (Fossum et al. 2002, Olmstead 2003). It can be bilateral and manifests as varying degrees of looseness of soft tissues adjacent to femoral head, acetabulum instability and malformation, and degenerative joint disease (DJD) (Brinker et al. 1999). It's a quantitative polygenic disease, influenced by non-genetic factors and characterized by well-defined phenotypic classes which includes normal and affected individuals with varying degrees of severity. Thus, some dogs may present HD-related genes without presenting the disease (Dal-Farra & Kilp 1998).

HD generally manifests as painful, gradually incapacitating condition, mainly affecting large and giant canine breeds (Piermattei & Flo 1997). Clinically, dysplastic dogs can present have no signs of pain (Dassler 2003).

Osteoarthritis or DJD is the most common phenotypic manifestation of HD (Smith et al. 2001), usually affects

¹ Received on October 14, 2008.

Accepted for publication on January 26, 2009.

² Departamento de Cirurgia e Anestesiologia Veterinária, Faculdade de Medicina Veterinária e Zootecnia (FMVZ), Universidade Estadual Paulista "Júlio de Mesquita Filho" (Unesp), Distrito de Rubião Júnior s/n, Botucatu, SP 18618-000, Brazil.

³ Departamento de Reprodução Animal e Radiologia Veterinária, FMVZ, Unesp, Botucatu, SP 18618-000. *Corresponding author: raquelsartor@yahoo.com.br

adult dogs (Brinker et al. 1999, Fossum et al. 2002) with clinical signs including limping after vigorous or prolonged exercise, giddiness, and articular crepitation and limited joint movement (Souza & Tudury 2003).

The diagnosis of HD is based on the history, clinical examination and radiographic findings. Currently, radiography is the only available method to conclusively demonstrate the presence or absence of anatomical changes associated with the disease in live animals. However, a radiographically normal pelvis does not exclude the possibility that HD could be transmitted to the offspring of that radiographically normal dog (Kealy & McAllister 2005).

There are different types of treatment for HD. Their indication will depend on age, degree of joint degeneration and function to be recovered in the affected dog and the owner's financial conditions (Riser 1996, Manley 1998, Fossum et al. 2002). Although numerous treatments have been described, none of them can provide total restoration of the dysplastic joint, (Piermattei & Flo 1997); thus, an optimal therapy is still in need.

Conservative treatment is only recommended for dogs slightly affected by HD or for young ones with the first limping episode (Olmstead 2003). This therapy consists in easing pain and consequently ameliorating the clinical signs (Manley 1998, Fossum et al. 2002). When the conservative therapy proves ineffective, surgical treatment is indicated.

A great variety of surgical techniques are described for canine HD treatment; among them are pectineal myectomy (Wallace & Olmstead 1995), intertrochanteric femoral osteotomy (Wallace & Omstead 1995, Piermattei & Flo 1997), total prosthesis of the hip joint (Perot 1984, Wallace & Omstead 1995, Minto et al. 2008), arthroplastic excision of the femoral head and neck (Iamaguti 1981, Piermattei & Flo 1997), extracapsular acetabuloplasty (Iamaguti et al. 1996, Ferreira et al. 2007), femoral head ligament restoration using *fascia lata* grafts (Brandão 1999), and acetabuloplasty with femoral head ligament reconstruction (Bergamo 2001).

Although there is a large number of available surgical techniques, too many severe canine HD cases without a satisfactory treatment are still observed in Brazil, mainly due to the socioeconomic limitations on the importation and use of prosthetic veterinary materials. A technique has been described (Bergamo 2001) as an alternative of relative low cost for the treatment of such cases. However, the method was only experimentally evaluated in dogs without joint alterations and a new study is necessary to evaluate its efficacy in dogs presenting severe HD.

This work aims to reproduce the technique previously described (Bergamo 2001) in dogs with severe HD, evaluating its efficacy and consequently presenting a new option for acetabular anatomy restoration, i.e. acetabuloplasty, with deepening the acetabular cavity and reconstructing the femoral head ligament and the joint capsule in dogs presenting severe HD.

MATERIALS AND METHODS

Nine 1-3-year-old Rottweiler, Labrador Retriever and German Shepherd dogs, of both sexes, that presented severe HD with acute subdislocation or dislocation of the femoral head, were included in this study. The dog had been referred to private clinics from Botucatu, Campinas and Osasco in São Paulo State, Brazil. After clinical and radiographic tests, they were subjected to surgical procedures described elsewhere (Bergamo 2001), which consisted in restoring the acetabular anatomy by acetabular cavity deepening and reconstruction of femoral head ligament and joint capsule. The technique was constituted of two phases: initially all nine dogs were subjected to bilateral pectinotomy. Within an interval of at least two weeks, the second surgical intervention was performed in the same nine dogs and a skin incision was made from the greater trochanter to lateral epicondyle of the femur. An incision was made and a strip of approximately 1.5cm was separated from the *fascia lata*. Femoral biceps divulsion allowed better visualization of the *gluteus medius* and *minimus*. The latter underwent partial tenotomy for exposure of the greater trochanter, which was sectioned using a saw, allowing the observation of the head of the femur and of the acetabulum. The totally distended femoral head ligament was sectioned in order to expose the acetabular cavity and perform the acetabular deepening by using an acetabular reamer. To reconstruct the femoral head ligament, a hole was made through the fovea towards the greater trochanter, beside another hole in the acetabulum in the same direction of the femoral head and neck canal. The *fascia lata* strip associated with a 0.60mm nylon thread was passed through the canals and sutured in the remaining joint capsule of the femoral neck after having passed through the acetabulum medial surface. The joint capsule was sutured and the greater trochanter was repositioned with bone suture using Sultan-type steel thread. The *gluteus minimus* tendon was sutured with 3-0 nylon thread in an interrupted pattern. The *fascia lata* strip with the nylon thread was retrogradely pulled and fixed in the aponeurosis of the greater trochanter region. *Fascia lata*, subcutaneous tissue and skin sutures were performed as usual. The dogs were evaluated at 30, 60 and 90 postoperative days and then at three years after surgery.

RESULTS AND DISCUSSION

In general, within 30 days of the surgery the dogs could stand on the operated member in order to walk. Except for two dogs which presented high degree of femoral head anteversion, all the others recovered pelvic member locomotive ability within 60-90 days after surgery.

In the case of a male, 4-year-old Labrador Retriever, the radiography prior to the surgical procedure showed that the left posterior member had an acute acetabular cavity reaming with femur dorsal subdislocation, suggesting severe HD (Fig.1A). Three years after surgery, the acetabular cavity deepening was evident and started to properly cover the femoral head, avoiding possible dislocations and subdislocations and providing higher joint stability. The formation of an osteophyte in the dorsal acetabular branch was also noticed, besides DJD development, with thickening of the neck and discreet femoral head deformation. Tests indicated that although the technique did not avoid the development of degene-

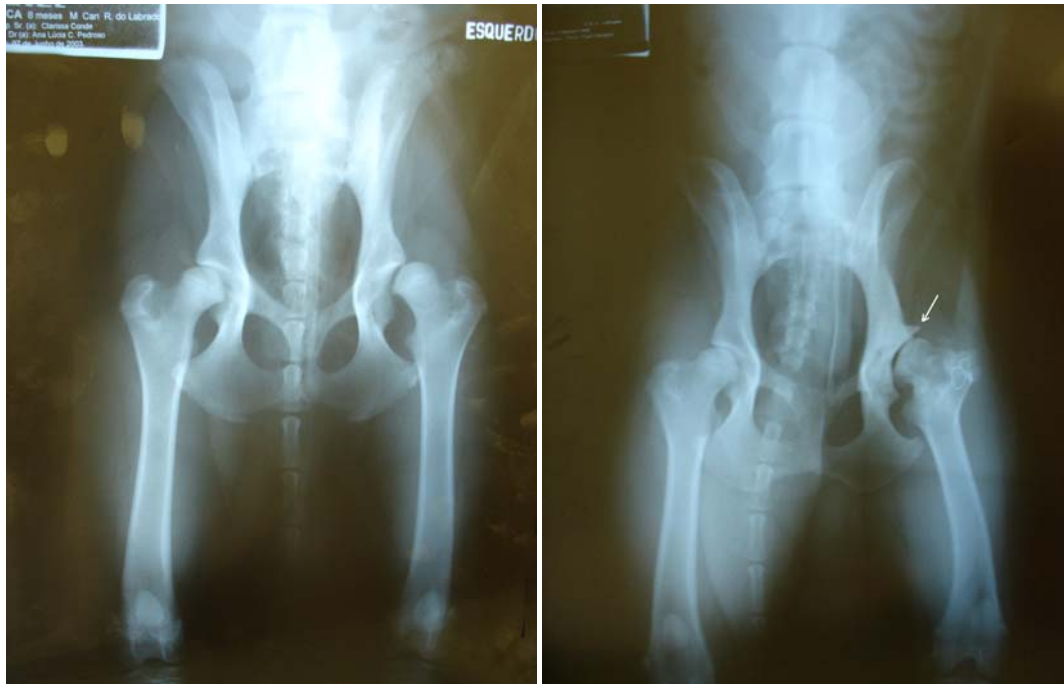


Fig.1. (A) Radiograph taken before surgery. Note that the left posterior member has an acute acetabular cavity reaming with femur dorsal subdislocation, suggesting severe hip dysplasia. (B) Radiograph taken three years after surgery. Deepening of the acetabular cavity and proper covering of the femoral head can be observed. Osteophyte in the dorsal branch of acetabulum (arrow), thickening of the neck and deformation of the head the femur were also evident.

rative alterations, it was effective in providing an ideal femoral head covering, keeping two-thirds of its medial to the dorsal acetabular edge, with good joint stability (Fig.1B).

A small number of dogs were evaluated because 80% of those subjected to pectinotomy in the first phase had experienced significant improvements and did not require a second surgical intervention. This work demonstrates a practical application of the experimental technique previously described (Bergamo 2001). In HD, often there is flattening of the acetabular cavity which leads to hip joint subdislocation and dislocation with rupture or laceration of the femoral head ligament (Brinker et al. 1999); therefore, the surgical technique was developed to deepen the flat acetabulum and restore the femoral head ligament. Changing the shape of the acetabulum in order to decrease subdislocation had been proposed earlier (Iamaguti et al. 1996, Manley 1998) through acetabular edge extension with bone fragments or polymers.

As previously observed (Piermattei & Flo 1997, Brandão 1999, Bergamo 2001) our findings corroborate that the dorsal access to the hip joint through greater trochanter osteotomy allowed good joint exposure. After the joint capsule incision, the femoral head ligament was split or lacerated, which facilitated its rupture with the aid of scissors. This provided adequate femoral head and acetabulum exposure and allowed an easy production of a bone canal for the *fascia lata* passage. The use of an acetabular reamer attached to a power drill allowed the

acetabular cavity deepening and the joint cartilage removal, reaching the subchondral bone as previously described (Bergamo 2001). The deepening was performed according to the inclination angle of the femoral head and neck. Special attention was given to locate the anatomical insertion sites of the fovea ligament in the femoral head and acetabular pit. The importance of the correct direction of holes to keep the fascia integrity has been highlighted (Pettit 1974, Duff & Bennett 1982). The joint capsule was sutured as this structure is considered of great importance for the hip joint stabilization (Pettit 1974, Piermattei & Flo 1997). When the joint capsule could not be identified, the periarticular tissues were re-approximated for the joint stabilization.

CONCLUSION

Hip joint incongruence resulting from severe hip dysplasia can be surgically treated by acetabular cavity deepening and restoration of the femoral head ligament and the joint capsule, with good functional results.

REFERENCES

- Bergamo F.M.M. 2001. Acetabuloplastia e reconstrução do ligamento da cabeça do fêmur com auto-enxerto de *fascia lata*, associado ou não ao sulfato de condroitina: padronização da técnica para o tratamento da displasia coxofemoral canina. Dissertação de Mestrado em Cirurgia Veterinária, Faculdade de Medicina Veterinária e Zootecnia, Unesp-Botucatu, Botucatu, SP. 93p.
- Brinker W.O., Piermattei D.L. & Flo G.L. 1999. A articulação coxofemoral,

- p.406-433. In:— (Ed.), *Manual de Ortopedia e Tratamento de Fraturas dos Pequenos Animais*. 3ª ed. Manole, São Paulo. 694p.
- Brandão C.V.S. 1999. Reconstituição do ligamento da cabeça do fêmur com auto-enxertos de fásia lata e trocânter maior na luxação experimental em cães. Tese de Doutorado sobre técnica para o tratamento da displasia coxofemoral canina. Dissertação de Mestrado em Cirurgia Veterinária, Faculdade de Medicina Veterinária e Zootecnia, Unesp, Botucatu, SP. 190p.
- Dal-Farra R.A. & Kılıp D.V. 1998. Fatores genéticos associados à displasia coxofemoral. *Hora Vet.*, Porto Alegre, 18:59-64.
- Dassler C.L. 2003. Canine hip dysplasia: diagnosis and non surgical treatment, p.2019-2029. In: Slatter D. (Ed.), *Textbook of Small Animal Surgery*. Vol.2. 3rd ed. Saunders, Philadelphia. 2896p.
- Duff S.R.I. & Bennett D. 1982. Hip luxation in small animals: An evaluation of some methods of treatment. *Vet. Rec.* 111:140-143.
- Ferreira M.P., Alievi M.M., Gomes C., Beck C.A.C., Voll J., Sia D., Filho A.P.F.S. & Freires C.D. 2007. Acetabuloplastia extra-capsular para tratamento de displasia coxofemoral em cães: relato de caso. *Acta Sci. Vet.* 35:101-104.
- Fossum T.W., Hedlund C.S. & Hulse D.A. 2002. *Cirurgia de Pequenos Animais*. Roca, São Paulo. 1408p.
- Iamaguti P. 1981. Aspectos da articulação coxofemoral após a excisão artroplástica da cabeça do fêmur em cães. Tese de Livre Docência em Cirurgia Veterinária, Faculdade de Medicina Veterinária e Zootecnia, Unesp, Botucatu, SP. 55p.
- Iamaguti P., Brandão C.V.S., Mamprim M.J., Inoe A.P. & Sampaio G. R. 1996. Acetabuloplastia extra-capsular com enxerto alógeno de arco zigomático conservado em glicerina a 98%. *Anais do 18º Congresso Brasileiro de Clínicos Veterinários de Pequenos Animais*, Olinda, p.46.
- Kealy J.K. & McAllister H. 2005. Ossos e articulações, p.253-338. In: —(Ed.), *Radiologia e Ultra-sonografia do Cão e do Gato*. 3ª ed. Manole, São Paulo. 436p.
- Manley P.A. 1998. Articulação coxofemoral, p.2113-2134. In: Slatter D. (Ed.), *Manual de Cirurgia de Pequenos Animais*. Vol. 2. 2ª ed. Manole, São Paulo. 2830p.
- Minto B.W., Brandão C.V.S., Pereira G.J.C., Steagall P.V.M., Mamprim M.J. & Ranzani J.J.T. 2008. Artroplastia total coxofemoral em cães: estudo experimental com prótese nacional. *Ciência Rural* 38:136-142.
- Olmstead M.L. 2003. Articulação coxofemoral, p.1138-1139. In: Birchard J.S. & Sherding R.G. (Ed.), *Manual Saunders: Clínica de Pequenos Animais*. 2ª ed. Roca, São Paulo. 1591p.
- Perot F. 1984. Total low friction canine prosthesis. *Sciences Vétérinaires et de Medecine Comparée* 86:193-197.
- Pettit G.D. 1974. Joints of the hindlimb, p.1067-1159. In: Archibald J. (Ed.), *Canine Surgery*. American Veterinary Publications, California. 1172p.
- Piermattei D.L. & Flo G.L. 1997. A articulação coxofemoral, p.394-436. In: Brinker W.O., Piermattei D.L. & Flo G.L. (Ed.), *Ortopedia e Tratamento das Fraturas em Pequenos Animais*. 3ª ed. Manole, São Paulo. 694p.
- Riser W.H. 1996. Displasia coxofemoral, p.924-932. In: Bojrab M.J. (Ed.), *Mecanismos da Moléstia na Cirurgia dos Pequenos Animais*. 2ª ed. Manole, São Paulo. 1446p.
- Smith G.K., Mayhew P.D. & Kapatkin A.S. 2001. Evaluation of risk factors for degenerative joint disease associated with hip dysplasia in German Shepherd Dogs, Golden Retrievers, Labrador Retrievers, and Rottweilers. *J. Am. Vet. Med. Assoc.* 219:1719-1724.
- Souza A.F.A. & Tudury E.A. 2003. Displasia coxofemoral: diagnóstico clínico e radiográfico: revisão. *Clínica Vet.* 47:54-66.
- Wallace L.J. & Olmstead M.L. 1995. Disabling conditions of canine coxofemoral joint, p.361-394. In: Olmstead M.L. (Ed.), *Small Animal Orthopedics*. Mosby, St Louis, Missouri. 591p.