


## Sedative and electrocardiographic effects of low dose dexmedetomidine in healthy cats<sup>1</sup>

Elizabeth Regina Carvalho<sup>2\*</sup> , Tatiana Champion<sup>2</sup>,  
Ricardo G. D’Otaviano C. Vilani<sup>3</sup>, Gabrielle C. Freitas<sup>2</sup>, Francielli Ambrosini<sup>2</sup>,  
Gabrieli A. Silva<sup>2</sup>, Karine S. Gonçalves<sup>2</sup> and Julio Cezar J. Fischborn<sup>2</sup>

**ABSTRACT.-** Carvalho E.R, Champion T, Vilani R.G.O.C., Freitas G.C., Ambrosini F, Silva G.A., Gonçalves K.S. & Fischborn J.C.J. 2019. **Sedative and electrocardiographic effects of low dose dexmedetomidine in healthy cats.** *Pesquisa Veterinária Brasileira* 39(2):142-171. Universidade Federal da Fronteira Sul, Rodovia BR-182 Km 466, Avenida Edmundo Gaievski 1000, Cx. Postal 253, Realeza, PR 85770-000, Brazil. E-mail: [beth\\_rcarvalho@hotmail.com](mailto:beth_rcarvalho@hotmail.com)

In feline veterinary practice sedation is often needed to perform diagnostic or minimally invasive procedures, minimize stress, and facilitate handling. The mortality rate of cats undergoing sedation is significantly higher than dogs, so it is fundamental that the sedatives provide good cardiovascular stability. Dexmedetomidine (DEX) is an  $\alpha_2$ -adrenergic receptor agonist utilized in cats to provide sedation and analgesia, although studies have been utilized high doses, and markedly hemodynamic impairments were reported. The aim of this study was to prospectively investigate how the sedative and electrocardiographic effects of a low dose of DEX performing in cats. Eleven healthy cats were recruited; baseline sedative score, systolic arterial pressure, electrocardiography, and vasovagal tonus index (VVTI) were assessed, and repeated after ten minutes of DEX 5 $\mu$ g/kg intramuscularly (IM). A smooth sedation was noticed, and emesis and sialorrhea were common adverse effects, observed on average seven minutes after IM injection. Furthermore, electrocardiographic effects of a low dose of DEX mainly include decreases on heart rate, and increases on T-wave amplitude. The augmentation on VVTI and appearance of respiratory sinus arrhythmia, as well as sinus bradycardia in some cats, suggesting that DEX enhances parasympathetic tonus in healthy cats, and therefore will be best avoid in patients at risk for bradycardia.

INDEX TERMS: Sedative, electrocardiographic effects, dexmedetomidine, healthy cats,  $\alpha_2$ -agonist, bradycardia, feline, sedation, T-wave, cats.

### RESUMO.- [Efeitos sedativos e eletrocardiográficos da baixa dose de dexmedetomidina em gatos saudáveis.]

Na rotina clínica da medicina veterinária felina a sedação é frequentemente requerida para realização de procedimentos diagnósticos ou minimamente invasivos, para minimizar o estresse e facilitar o manuseio dos pacientes. A taxa de mortalidade de gatos submetidos à sedação é mais elevada do que em cães, por esse motivo, é fundamental que os sedativos confirmem estabilidade hemodinâmica. A dexmedetomidina

(DEX) é um  $\alpha_2$ -agonista utilizado em felinos para promover sedação e analgesia, porém os estudos têm utilizado doses elevadas, e com isso prejuízos hemodinâmicos importantes foram relatados. O objetivo desta investigação foi avaliar os efeitos sedativos e eletrocardiográficos da baixa dose de DEX em gatos. Para tal, onze felinos saudáveis foram recrutados, foram obtidos valores basais para escore de sedação, pressão arterial sistólica e eletrocardiografia, além do índice de tônus vaso vago (ITVV). Após dez minutos da aplicação intramuscular (IM) de DEX 5 $\mu$ g/kg todos os exames foram repetidos. Após a DEX, sedação suave foi detectada, e a êmese e sialorreia foram efeitos adversos comuns, observados em média 7 minutos após a injeção IM. Ademais, os principais efeitos eletrocardiográficos foram redução na frequência cardíaca e aumento na amplitude da onda T. O ITVV mais elevado e surgimento de arritmia sinusal respiratória, bem como bradicardia sinusal em alguns gatos, sugerem que a

<sup>1</sup> Received on August 23, 2018.

Accepted for publication on September 18, 2018.

<sup>2</sup> Universidade Federal da Fronteira Sul, Rodovia BR-182 Km 466, Avenida Edmundo Gaievski 1000, Cx. Postal 253, Realeza, PR 85770-000, Brazil.

\*Corresponding author: [beth\\_rcarvalho@hotmail.com](mailto:beth_rcarvalho@hotmail.com)

<sup>3</sup> Laboratório de Anestesiologia e Analgesia Veterinária, Universidade Federal do Paraná, Rua dos Funcionários, 1540, Curitiba, PR 80035-050, Brazil.

DEX eleva o tônus parassimpático, e por esse motivo deve ser utilizada com cautela em pacientes com predisposição à bradicardia.

**TERMOS DE INDEXAÇÃO:** Sedativos, eletrocardiografia, dexmedetomidina, gatos saudáveis,  $\alpha_2$ -agonista, bradicardia, felinos, sedação, onda T.

## INTRODUCTION

In feline veterinary practice sedation is often needed to perform diagnostic or minimally invasive procedures, minimize stress, and facilitate handling. An ideal sedation protocol allows for quick and smooth decreased responsiveness while maintaining cardiopulmonary function and providing quiet recovery (Cremer & Riccò 2017). The mortality rate of cats undergoing sedation is significantly higher than dogs (0.12% vs 0.07%), and one of limitations is due to sedation monitoring of physiologic variables is usually more limited/underestimated than under general anesthesia, so it is important that the sedatives provide good cardiovascular stability (Brodbeil et al. 2008).

Sedation and analgesia are prominent effects of central  $\alpha_2$ -adrenergic receptor activation, and these effects have been reported with agents such as xylazine, medetomidine, and romifidin in cats (Granhölm et al. 2006). Dexmedetomidine (DEX) is a highly selective  $\alpha_2$ -adrenergic receptor agonist, the active enantiomer of racemic medetomidine, that induces dose-dependent sedation, analgesia and muscle relaxation in cats (Ansah et al. 1998). However, studies reporting sedative effects of this drug in cats mainly utilized high doses of DEX (10- 75 $\mu$ g/kg), and indeed marked decreases in heart rate, cardiac output, and transient changes in blood pressure were noticed (Ansah et al. 1998, Selmi et al. 2003, Granhölm et al. 2006), moreover the electrocardiographic effects of DEX has not been completely characterized in this species.

The electrocardiography (ECG) is a widely used exam in veterinary medicine, mainly to detect/exclude arrhythmias, as part of pre-anesthetic evaluation, and/or cardiac monitoring in patients under intensive care unit, or during general anesthesia. In cats, additional clinical applications include assessment of cardiac dimensions, for which an ECG is a poor substitute for an echocardiogram (Pellegrino et al. 2016), and monitoring of extracardiac disturbances that could possible lead to cardiac impairments, such as hyperkalemia in cats with urethral obstruction, oliguric/anuric renal failure, reperfusion injury (Schaer 1977, Côté 2010, Garcia de Carellan Mateo et al. 2015), or hypoxemia (Boyden 1992). The aim of this study was to prospectively investigate how the sedative and electrocardiographic effects of a low dose of DEX performing in healthy cats.

## MATERIALS AND METHODS

**Study design and ethics statement.** This was a prospective cohort study, performed with the ethical approval of the Federal University of Fronteira Sul Committee for Animal Experimentation (protocol number 23205.004198/2017-56).

**Animals.** Eleven client-owned adult domestic shorthair male cats were recruited for the study. Cats were considered healthy based on clinical examination, routine hematology, systolic arterial pressure (SAP), electrocardiography (ECG), and echocardiography - in order to exclude heart diseases. These values were within

published reference intervals for complete blood count (Feldman et al. 2000), SAP (Brown et al. 2007), ECG (Tilley & Burtinick 1999), and echocardiography (Boon 2011). Animals were fasted for 12 hours, but had free access to water until 2 hours prior to sedation.

**Baseline sedative score.** On the day of the experiment each cat was weighed, a physical examination was performed and they had their hair clipped on right and left thoracic limbs palmar faces. Cats were acclimated to cardiology exam room during 30 minutes before measurements. The baseline sedative score was assessed by a single and experienced anesthesiologist, using a subjective scoring criteria proposed by Granhölm et al. 2006 to evaluate sedation on cats treated with DEX or medetomidine. This scoring criteria ranges from zero to twelve, where the biggest score corresponds to deeper sedation, and takes into account spontaneous posture, response to noise, muscle tone of jaw and tongue, as well as pedal withdrawal response to pinching of a digit or interdigital web.

**Baseline SAP measurement.** After evaluation of sedative score, the animal was gently positioned on right lateral recumbence, a cuff size corresponding to 30-40% of the distal radius diameter was utilized (Brown et al. 2007), and SAP was obtained with a vascular Doppler (Medmega, Franca, Brazil) attached to a sphygmomanometer. Five consecutive measurements were made, minimum and maximum values were excluded and a mean of the other three was recorded.

**Baseline electrocardiographic assessment.** Posteriorly, also on right lateral recumbence (Harvey et al. 2005), a six leads ECG (ECGPC TEB, Tecnologia Eletrônica Brasileira, São Paulo, Brazil) was recorded over two-minutes. In order to obtain the bipolar leads I, II and III, as well as increased unipolar leads aVR, aVL and aVF, the right (red) and left (yellow) thoracic electrodes were fixed above the olecranon region, and the right (black) and left (green) pelvic electrodes above the patellar ligaments (Tilley 1992), alcohol 70% was instilled among skin and electrodes to improve electric reciprocity. The register speedy was adjusted to 50mm/s, and calibration of 1mV=1cm. All measurements were made in triplicate, on lead II, by a single and experienced observer, as follows: predominant heart rhythm, heart rate (HR), P-wave width and amplitude, PR interval, QRS complex width, R-wave amplitude, QT interval, T-wave polarity and width, and ST leveling and morphology, according previously described (Tilley & Burtinick 1999). The rate-corrected QT interval (QTc) was calculated from the following equation (Van de Water et al. 1989):  $QTc = QT - 0.087(RR - 1000)$ . Furthermore, the ECG tracings were reviewed to presence of arrhythmias (atrioventricular blocks of second and/or third degrees, ventricular ectopic beats, atrial premature contractions, junctional P-waves or junctional ectopic beats), as described elsewhere (Tilley 1992, Tilley & Burtinick 1999). Also on lead II, the first 20 consecutive R-R intervals in which cardiac rhythm was of sinus origin were used to calculate vasovagal tonus index (VVTI) for each patient. The index was obtained by calculating the natural logarithm of the variance of the 20 measured R-R intervals, as described by the equation  $VVTI = NL[\text{VAR}(R-R1 - R-R20)]$ , where NL: natural logarithm, VAR: variance (Häggström et al. 1996).

**Sedation.** After all baseline measurements previously described, cats received 5 $\mu$ g/kg of DEX (Dexdormitor, Zoetis) intramuscularly (IM) and were housed in cages on cardiology exam room during ten minutes. Adverse effects as emesis and sialorrhoea were recorded. Ten minutes apart from IM injection, the sedation score was accessed, followed by SAP and ECG recording, as described above.

**Statistical analysis.** All analyses were performed using the software GraphPad Prism (Version 5.0 - San Diego/CA, USA). The D'Agostino and Pearson omnibus normality test was used to investigate data distribution. Comparisons between baseline measurements and

post-sedation were accomplished by either Mann-Whitney test or Student's t-test, according to distribution. Associations between qualitative variables were analyzed with Fisher's exact test. Correlation among HR and VVTI was accomplished by Pearson test. Statistical significance was defined as  $P < 0.05$ .

## RESULTS

Baseline mean sedation score was 0 (ranging from 0 to 0, minimum and maximum), and 3 (ranging from 0 to 8, minimum and maximum) post sedation ( $P=0.0022$ ). None of animals achieved lateral recumbency after low dose of DEX. The baseline SAP was  $118 \pm 9$  mmHg, and  $130 \pm 14$  mmHg after sedation ( $P=0.0421$ ). Six cats (55%) exhibited sialorrhea and emesis after 3 to 15 minutes of DEX injection, between then, two animals (33%) had a second episode of vomiting 5 to 8 minutes apart.

Descriptive statistics of electrocardiographic assessment in healthy cats submitted to sedation with dexmedetomidine is shown in Table 1. The HR was considered different among

**Table 1. Descriptive statistics of electrocardiographic assessment in healthy cats submitted to sedation with dexmedetomidine (DEX)  $5 \mu\text{g}/\text{kg}$  IM. Parametric data are shown as mean  $\pm$  standard deviation, while non-parametric variables are represented as median (interquartile range)**

Measurement	P	Baseline	After DEX
Heart rate (bpm)	0.0028	187 (132-201)	96 (89-126)
P (ms)	0.9439	47 (43-48)	47 (43-49)
PR (ms)	0.1013	$72 \pm 9$	$79 \pm 6$
QRS (ms)	0.6147	47 (43-55)	47 (43-48)
QT (ms)	0.1869	$183 \pm 25$	$200 \pm 29$
QTc (ms)	0.9616	$239 \pm 25$	$238 \pm 22$
P (mV)	0.3756	0.13 (0.08-0.14)	0.09 (0.09-0.12)
R (mV)	0.1496	$0.48 \pm 0.17$	$0.56 \pm 0.15$
T (mV)	0.0236	0.10 (0.07-0.14)	0.18 (0.12-0.25)
VVTI	0.0433	$2.68 \pm 0.60$	$3.34 \pm 0.86$

VVTI = Vasovagal tonus index.

moments ( $P=0.0028$ ), being significantly slower after DEX. The T-wave amplitude increased after sedation ( $P=0.0236$ ), although no cat presented a T-wave  $> 0.3$  mV. Concerning the T-wave polarity, two patients (18%) changed the polarity after DEX (one cat had a biphasic T-wave that turned only positive after sedation, and another had a negative T-wave that turned positive), but no statistical difference was detected ( $P=0.4762$ ). No changes on ST segment were seen after DEX.

At baseline all animals presented sinus rhythm, while after DEX four cats (36%) presented respiratory sinus arrhythmia (RSA), defined as a naturally occurring variation of R-R interval bigger than 20% during breathing cycle (Tilley & Burtinick 1999), and three animals (27%) became bradycardic (88-94bpm), defined as  $\text{HR} < 100$  bpm (Tilley & Burtinick 1999). Figure 1 illustrates a RSA detected post sedation.

After DEX, the VVTI was considered bigger than it was at baseline ( $P=0.0433$ ), as shown in Figure 2. All the other electrocardiographic measurements were found to be similar between moments. VVTI and HR were not considered correlated ( $P=0.0564$ ;  $R = -0.47$ ; 95% of confidence interval = -0.76 to 0.01).

## DISCUSSION

This study showed that a low dose of DEX on pre-medication produces a smooth sedation in cats (average 3 points), when a subjective scoring criterion graduated from zero to twelve was utilized. None of animals achieved lateral recumbency, and physical restraint to perform ECG after sedation was laborious in three cats (two scored zero, and another scored one point). Limited data are available on the sedative effects with low doses of DEX alone in cats, most of them are reports with the labeled dose, ranging from 20 to  $40 \mu\text{g}/\text{kg}$  (Johard et al. 2018, Martin-Flores et al. 2018). In another study, Selmi et al. 2003 reported a satisfactory sedation and lateral recumbence in all cats after DEX  $10 \mu\text{g}/\text{kg}$  IM. Previously studies suggesting that sedation occurs in a dose related manner (Ansah et al. 1998, Johard et al. 2018, Martin-Flores et al. 2018), and associations with opioids (Johard et al. 2018) and/or ketamine (Cremer & Riccò 2017) promote more intense sedative effects in cats.

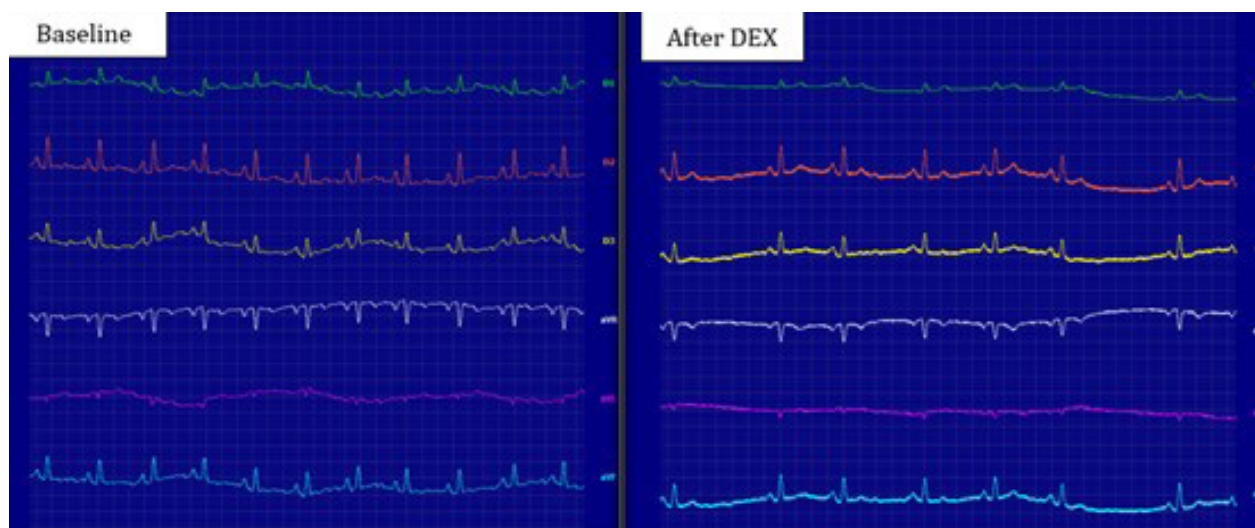


Fig.1. Heart rhythm of a cat from this study. At baseline it was recorded a sinus rhythm and heart rate of 187bpm, after ten minutes of dexmedetomidine  $5 \mu\text{g}/\text{kg}$  IM it was noticed a respiratory sinus arrhythmia (RSA) and heart rate ranging from 108-139bpm. The RSA is not considered a physiological heart rhythm in cats. Electrocardiographic tracings were both recorded at 50mm/s and 2N amplitude.

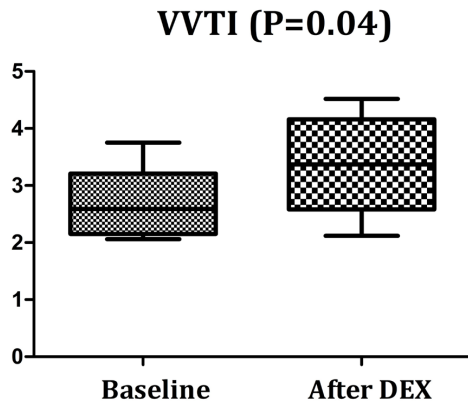


Fig.2. Box plot depicting the medians, interquartile ranges and amplitude of vasovagal tonus index (VVTI) in healthy cats at baseline and after being submitted to sedation with dexmedetomidine 5µg/kg IM.

The incidence of emesis on this investigation was considerable higher than the 7% anteriorly reported with high dose (40µg/kg IM) administration (Granholm et al. 2006). Similarly, Selmi et al. 2003 did not noticed emetic events after 10µg/kg IM in healthy cats. However, another group of researchers showed that 78% of cats sedated with DEX (4 µg/kg) plus buprenorphine (20µg/kg) IM vomited at 0 to 13 minutes post-injection (Santos et al. 2011). The fasting period was 12 hours on both ours and the above-mentioned experiments.

When DEX binds to α<sub>2</sub>-adrenergic receptor on the vascular smooth muscle, systemic vascular resistance increases (Ruffolo Junior 1985, Duka et al. 2000) ultimately leading to increases on systemic arterial blood pressure (Bloor et al. 1992, Martin-Flores et al. 2018). After pre-medication, SAP significantly increased (130±14mmHg) from baseline (118±9 mmHg). Overall, this smooth rise is well tolerated in healthy animals, and SAP <150mmHg is considered by the American College of Veterinary Internal Medicine - *Guidelines for the identification, evaluation, and management of systemic hypertension in dogs and cats* - as minimal risk of future target organ damage (Brown et al. 2007). Although, it seems reasonable that caution should be taken in cats already hypertensive, as frequently observed in hyperthyroidism (Stiles et al. 1994) and chronic kidney disease (Stiles et al. 1994, Sander et al. 1998), despite no studies have been addressed to the use of DEX in such individuals, at author's knowledge.

The vasopressor action of DEX increases arterial and pulmonary pressures, leading to reflex bradycardia (Devic et al. 1994, McSweeney et al. 2012). According to our findings, the concomitant decrease in HR and increases in SAP after DEX might suggest a reflex phenomenon in cats. Moreover, it has been reported that this drug decreases sympathetic nervous system tone and increases parasympathetic nervous system activity within the central nervous system, decreasing both GABAergic and glycinergic inhibitory input to cardiac vagal neurons, which may contribute to the bradycardia (Sharp et al. 2014).

The VVTI is a useful time domain indicator of heart rate variability obtained from the standard ECG, being mainly influenced by the parasympathetic tone, as recognized in

previous studies (Häggström et al. 1996, Pereira et al. 2008, Kocabaş et al. 2009, Brüler et al. 2017, Pecceu et al. 2017). Indeed, the lower HR and the higher VVTI seen after DEX in this study are indicative of increased parasympathetic tonus. In addition, the RSA noticed in some cats after sedation is another evidence that a parasympathetic activation was markedly present (Wardlaw 1985). The RSA is a regular irregular rhythm, considered a physiologic heart rhythm in dogs (Tilley 1992, Tilley & Burtinick 1999) and healthy human beings (Cooke 1998, Sturgeon et al. 2014). In cats at the clinical setting, RSA is not normally seen, and is usually considered pathologic (Rishniw & Bruskiwicz 1996), once normal rhythms in healthy subjects include sinus rhythm and sinus tachycardia (>240bpm) due to handling excitement (Tilley & Burtinick 1999). However, some studies have indicated that healthy cats in their home environment (Hanås et al. 2009) or under general anesthesia (Lewis et al. 2013) commonly have periods of RSA.

It was already well characterized that DEX significantly depressed sinus and atrioventricular nodal function in human pediatric patients (Hammer et al. 2008). However, it was shown in previously studies that DEX did not have a direct effect on ventricular or atrial refractoriness, and spontaneous atrioventricular block was not reported in patients with normal baseline atrioventricular nodal conduction (Hammer et al. 2008, Chrysostomou et al. 2010, Char et al. 2013). Similarly, it was found no difference between PR interval at baseline and post low dose of DEX, also all measurements were within reference values to cats (PR interval: 50-90 ms) (Tilley & Burtinick 1999). This finding differ from those reported with xylazine in dogs (Klide et al. 1975, Haskins et al. 1986), and romifidine administration in horses (Clarke et al. 1991, Freeman et al. 2002), once these two less selective α<sub>2</sub>-adrenergic receptor agonists promoted second degree atrioventricular block in such species.

On ECG, the T-wave represents rapid ventricular repolarization (i.e. phase 3) of the ventricular action potential (Issa et al. 2009). During phase 3, there is closure of the calcium channels, while the potassium channels remain open, resulting in rapid loss of positive charge from the cardiomyocytes and restoration of the resting membrane potential (Issa et al. 2009). As such, the configuration of the T wave is dependent on the spatial-temporal characteristics of ventricular repolarization (Lin et al. 2013). The T-wave in cats can be positive, negative, or biphasic (Tilley & Burtinick 1999). A relation between low dose of DEX in cats and direct effects of such drug over ventricular repolarization could be anticipated, although measurements remained within reference values (T wave <0.3mV). Furthermore, more studies should be addressed to investigate if this possible effect of DEX is indeed related to ventricular repolarization or not.

## CONCLUSIONS

A low dose of dexmedetomidine (5µg/kg IM) alone produces a smooth sedation in cats, and handling to minimally invasive procedures could be difficult in non-collaborative animals. Emesis and sialorrhea are common adverse effects, observed on average seven minutes after intramuscularly (IM) injection. Even a low dose of DEX increases systolic arterial pressure in healthy cats, although nonehypertensive episodes were recorded.

Furthermore, electrocardiographic effects of a low dose of DEX mainly include decreases on heart rate, and increases on T-wave amplitude. The augmentation on vasovagal tonus index and appearing of respiratory sinus arrhythmia, as well as sinus bradycardia in some cats, suggesting that DEX enhances parasympathetic tonus in healthy cats, and therefore will be best avoid in patients at risk for bradycardia.

**Conflict of interest statement.** - The authors have no competing interests.

## REFERENCES

- Ansah O.B., Raekallio M. & Vainio O. 1998. Comparison of three doses of dexmedetomidine with medetomidine in cats following intramuscular administration. *J. Vet. Pharmacol. Ther.* 21(5):380-387. <<http://dx.doi.org/10.1046/j.1365-2885.1998.00155.x>> <PMid:9811439>
- Bloor B.C., Frankland M., Alper G., Raybould D., Weitz J. & Shurtliff M. 1992. Hemodynamic and sedative effects of dexmedetomidine in dog. *Pharmacol. Exp. Ther.* 263(2):690-697. <PMid:1359110>
- Boon J. 2011. Evaluation of size, function and hemodynamics, p.151-260. In: *Ibid.* (Ed), *Veterinary Echocardiography*. 2nd ed. John Wiley & Sons, Ames.
- Boyden P.A. 1992. Cellular electrophysiologic basis of cardiac arrhythmias, p.273-286. In: *Tilley L.P.* (Ed), *Essentials of Canine and Feline Electrocardiography: interpretation and treatment*. 3rd ed. Mosby, Philadelphia.
- Brodbeck D.C., Blissitt K.J., Hammond R.A., Neath P.J., Young L.E., Pfeiffer D.U. & Wood J.L. 2008. The risk of death: the confidential enquiry into perioperative small animal fatalities. *Vet. Anaesth. Analg.* 35(5):365-373. <<http://dx.doi.org/10.1111/j.1467-2995.2008.00397.x>> <PMid:18466167>
- Brown S., Atkins C., Bagley R., Carr A., Cowgill L., Davidson M., Egner B., Elliott J., Henik R., Labato M., Littman M., Polzin D., Ross L., Snyder P. & Stepien R. 2007. Guidelines for the identification, evaluation, and management of systemic hypertension in dogs and cats. *Vet. Clin. N. Am., Small Anim. Pract.* 21(3):542-558. <PMid:17552466>
- Brüler B.C., Giannico A.T., Dittrich G. & Sousa M.G. 2017. Vasovagal tonus index in dog with myxomatous mitral valve disease. *Pesq. Vet. Bras.* 37(10):1181-1186. <<http://dx.doi.org/10.1590/s0100-736x2017001000023>>
- Char D., Drover D.R., Motonaga K.S., Gupta S., Miyake C.Y., Dubin A.M. & Hammer G.B. 2013. The effects of ketamine on dexmedetomidine-induced electrophysiologic changes in children. *Pediatr. Anesth.* 23(10):898-905. <<http://dx.doi.org/10.1111/pan.12143>> <PMid:23506472>
- Chrysostomou C., Komarlu R., Lichtenstein S., Shiderly D., Arora G., Orr R., Wearden P.D., Morell V.O., Munoz R. & Jooste E.H. 2010. Electrocardiographic effects of dexmedetomidine in patients with congenital heart disease. *Intensive Care Med.* 36(5):836-842. <<http://dx.doi.org/10.1007/s00134-010-1782-z>> <PMid:20213075>
- Clarke K.W., England G.C.W. & Goossens L. 1991. Sedative and cardiovascular effects of romifidine, alone and in combination with butorphanol, in the horse. *J. Vet. Anaesth.* 18(1):25-29. <<http://dx.doi.org/10.1111/j.1467-2995.1991.tb00008.x>>
- Cooke W.H. 1998. Respiratory sinus arrhythmia and cardiovascular neural regulation in athletes. *Med. Sci. Sports Exerc.* 30(7):1179-1180. <<http://dx.doi.org/10.1097/00005768-199807000-00027>> <PMid:9662693>
- Côté E. 2010. Feline arrhythmias: an update. *Vet. Clin. N. Am., Small Anim. Pract.* 40(4):643-650. <<http://dx.doi.org/10.1016/j.cvsm.2010.04.002>> <PMid:20610016>
- Cremer J. & Riccò C.H. 2017. Cardiovascular, respiratory and sedative effects of intramuscular alfaxalone, butorphanol and dexmedetomidine compared with ketamine, butorphanol and dexmedetomidine in healthy cats. *J. Feline Med. Surg.* 20(10):973-979. <PMid:29192545>
- Devic A., Schmeling W.T., Kampine J.P. & Wartier D.C. 1994. Oral dexmedetomidine preserves baroreceptor function and decreases anesthetic requirements of halothane-anesthetized dogs. *Anesthesiology* 81(2):419-430. <<http://dx.doi.org/10.1097/0000542-199408000-00021>> <PMid:8053593>
- Duka I., Gavras I., Johns C., Handy D.E. & Gavras H. 2000. Role of the post-synaptic alpha(2)-adrenergic receptor subtypes in catecholamine-induced vasoconstriction. *Gen. Pharmacol.* 34(2):101-106. <[http://dx.doi.org/10.1016/S0306-3623\(00\)00051-3](http://dx.doi.org/10.1016/S0306-3623(00)00051-3)> <PMid:10974417>
- Feldman B.F., Zinkl J.G. & Jain N.C. 2000. *Shalm's Veterinary Hematology*. 5th ed. Lippincott Williams & Wilkins, Philadelphia, p.1120-1124.
- Freeman S.L., Bowen I.M., Bettschart-Wolfensberger R., Alibhai H.I. & England G.C. 2002. Cardiovascular effects of romifidine in the standing horse. *Res. Vet. Sci.* 72(2):123-129. <<http://dx.doi.org/10.1053/rvsc.2001.0533>> <PMid:12027592>
- Garcia de Carellan Mateo A., Brodbelt D., Kulendra N. & Alibhai H. 2015. Retrospective study of the perioperative management and complications of ureteral obstruction in 37 cats. *Vet. Anaesth. Analg.* 42(6):570-579. <<http://dx.doi.org/10.1111/vaa.12250>> <PMid:25732861>
- Granhölm M., McKusick B.C., Westerholm F.C. & Aspegren J.C. 2006. Evaluation of the clinical efficacy and safety of dexmedetomidine or medetomidine in cats and their reversal with atipamezole. *Vet. Anaesth. Analg.* 33(4):214-223. <<http://dx.doi.org/10.1111/j.1467-2995.2005.00259.x>> <PMid:16764585>
- Häggström J., Hamlin R.L., Hansson K. & Kvarn C. 1996. Heart rate variability in relation to severity of mitral regurgitation in Cavalier King Charles spaniels. *J. Small Anim. Pract.* 37(2):69-75. <<http://dx.doi.org/10.1111/j.1748-5827.1996.tb01941.x>> <PMid:8656596>
- Hammer G.B., Drover D.R., Cao H., Jackson E., Williams G.D., Ramamoorthy C., Van Hare G.F., Niksch A. & Dubin A.M. 2008. The effects of dexmedetomidine on cardiac electrophysiology in children. *Vet. Anesth. Analg.* 106(1):79-83. <<http://dx.doi.org/10.1213/01.ane.0000297421.92857.4e>> <PMid:18165557>
- Hanäs S., Tidholm A., Egenvall A. & Holst B.S. 2009. Twenty-four hour Holter monitoring of unsedated healthy cats in the home environment. *J. Vet. Cardiol.* 11(1):17-22. <<http://dx.doi.org/10.1016/j.jvc.2008.10.003>> <PMid:19457726>
- Harvey A.M., Faena M., Darke P.G.G. & Ferasin L. 2005. Effect of body position on feline electrocardiographic recordings. *J. Vet. Intern. Med.* 19(4):533-536. <<http://dx.doi.org/10.1111/j.1939-1676.2005.tb02723.x>> <PMid:16097093>
- Haskins S.C., Patz J.D. & Farver T.B. 1986. Xylazine and xylazine-ketamine in dogs. *Am. J. Vet. Res.* 47(3):636-641. <PMid:3963565>
- Issa Z.F., Miller J.M. & Zipes D.P. 2009. Electrophysiological mechanisms of cardiac arrhythmias, p.1-25. In: *Ibid.* (Eds), *Clinical Arrhythmology and Electrophysiology: a companion to Braunwald's heart disease*. Elsevier, Philadelphia.
- Johard E., Tidholm A., Ljungvall I., Häggström J. & Höglund K. 2018. Effects of sedation with dexmedetomidine and buprenorphine on echocardiographic variables, blood pressure and heart rate in healthy cats. *J. Feline Med. Surg.* 20(6):554-562. <PMid:28718693>
- Klide A.M., Calderwood H.W. & Soma L.R. 1975. Cardiopulmonary effects of xylazine in dogs. *Am. J. Vet. Res.* 36(7):931-935. <PMid:1147358>
- Kocabaş U., Kaya E.B., Aytemir K., Yorgun H., Kepez A., Aksoy H., Ateş A.H., Tulumen E., Deveci O.S., Kabakci G., Tokgozoğlu L., Nazlı N., Ozkutlu H. & Oto A. 2009. A novel method for the diagnosis of neurocardiogenic syncope: heart rate recovery index. *Cardiology.* 114(1):50-55. <<http://dx.doi.org/10.1159/000212079>> <PMid:19365115>
- Lewis K.A., Scansen B.A. & Aarnes T.K. 2013. ECG of the month: respiratory sinus arrhythmia in an anesthetized cat. *J. Am. Vet. Med. Assoc.* 242(5):623-625. <<http://dx.doi.org/10.2460/javma.242.5.623>> <PMid:23402408>
- Lin W.Q., Teo S.G. & Poh K.K. 2013. Electrocardiography series: electrocardiographic T wave abnormalities. *Singapore Med. J.* 54(11):606-610. <<http://dx.doi.org/10.11622/smedj.2013218>> <PMid:24276094>

- Martin-Flores M., Sakai D.M., Honkavaara J. & Campoy L. 2018. Hemodynamic effects of low-dose atipamezole in isoflurane-anesthetized cats receiving an infusion of dexmedetomidine. *J. Feline Med. Surg.* 20(6):571-577. <<http://dx.doi.org/10.1177/1098612X17722265>> <PMid:28766985>
- McSweeney P.M., Martin D.D., Ramsey D.S. & McKusick B.C. 2012. Clinical efficacy and safety of dexmedetomidine used as a preanesthetic prior to general anesthesia in cats. *J. Am. Vet. Med. Assoc.* 240(4):404-412. <<http://dx.doi.org/10.2460/javma.240.4.404>> <PMid:22309012>
- Pecceu E., Stebbing B., Martinez Pereira Y., Handel I., Culshaw G., Hodgkiss-Geere H. & Lawrence J. 2017. Vasovagal tonus index (VVTI) as an indirect assessment of remission status in canine multicentric lymphoma undergoing multi-drug chemotherapy. *Vet. Res. Commun.* 41(4):249-256. <<http://dx.doi.org/10.1007/s11259-017-9695-8>> <PMid:28791606>
- Pellegrino A., Daniel A.G.T., Pessoa R., Guerra J.M., Lucca G.G., Goissis M.D., Freitas M.F., Cogliati B. & Larsson M.H.M.A. 2016. Sensibilidade e especificidade do exame eletrocardiográfico na detecção de sobrecargas atriais e/ou ventriculares em gatos da raça Persa com cardiomiopatia hipertrófica. *Pesq. Vet. Bras.* 36(3):187-196. <<http://dx.doi.org/10.1590/S0100-736X2016000300007>>
- Pereira Y.M., Woolley R., Culshaw G., French A. & Martin M. 2008. The vasovagal tonus index as a prognostic indicator in dogs with dilated cardiomyopathy. *J. Small. Anim. Pract.* 49(11):587-592. <<http://dx.doi.org/10.1111/j.1748-5827.2008.00654.x>> <PMid:19006490>
- Rishniw M. & Bruskiwicz K. 1996. ECG of the month. Respiratory sinus arrhythmia and wandering pacemaker in a cat. *J. Am. Vet. Med. Assoc.* 208(11):1811-1812. <PMid:8675464>
- Ruffolo Junior R.R. 1985. Distribution and function of peripheral alpha-adrenoceptors in the cardiovascular system. *Pharmacol. Biochem. Behav.* 22(5):827-833. <[http://dx.doi.org/10.1016/0091-3057\(85\)90535-0](http://dx.doi.org/10.1016/0091-3057(85)90535-0)> <PMid:2989947>
- Sander C., Horauf A. & Reusch C. 1998. Indirect blood pressure measurement in cats with diabetes mellitus, chronic nephropathy and hypertrophic cardiomyopathy. *Tierarztl. Prax., Ausg. K, Klientiere Heimtiere* 26(2):110-118. <PMid:9587982>
- Santos L.C.P., Ludders J.W., Erb H.N., Martin-Flores M., Basher K.L. & Kirch P. 2011. A randomized, blinded, controlled trial of the antiemetic effect of ondansetron on dexmedetomidine-induced emesis in cats. *Vet. Anaesth. Analg.* 38(4):320-327. <<http://dx.doi.org/10.1111/j.1467-2995.2011.00619.x>> <PMid:21645198>
- Schaer M. 1977. Hyperkalemia in cats with urethral obstruction: electrocardiographic abnormalities and treatment. *Vet. Clin. N. Am., Small Anim. Pract.* 7(2):407-414. <[http://dx.doi.org/10.1016/S0091-0279\(77\)50038-X](http://dx.doi.org/10.1016/S0091-0279(77)50038-X)> <PMid:867738>
- Selmi A.L., Mendes G.M., Lins B.T., Figueiredo J.P. & Barbudo-Selmi G.R. 2003. Evaluation of the sedative and cardiorespiratory effects of dexmedetomidine, dexmedetomidine-butorphanol, and dexmedetomidine-ketamine in cats. *J. Am. Vet. Med. Assoc.* 222(1):37-41. <<http://dx.doi.org/10.2460/javma.2003.222.37>> <PMid:12523477>
- Sharp D.B., Wang X. & Mendelowitz D. 2014. Dexmedetomidine decreases inhibitory but not excitatory neurotransmission to cardiac vagal neurons in the nucleus ambiguus. *Brain Res.* 1574:1-5. <<http://dx.doi.org/10.1016/j.brainres.2014.06.010>> <PMid:24933328>
- Stiles J., Polzin D.J. & Bistner S.I. 1994. The prevalence of retinopathy in cats with systemic hypertension and chronic renal failure or hyperthyroidism. *J. Am. Anim. Hosp. Assoc.* 30:564-572.
- Sturgeon J.A., Yeung E.W. & Zautra A.J. 2014. Respiratory sinus arrhythmia: a marker of resilience to pain induction. *Int. J. Behav. Med.* 21(6):961-965. <<http://dx.doi.org/10.1007/s12529-014-9386-6>> <PMid:24421149>
- Tilley L.P. 1992. *Essentials of Canine and Feline Electrocardiography*. 7th ed. Lea and Febiger, Philadelphia. 500p.
- Tilley L.P. & Burtinick N.L. 1999. *Electrocardiography for the Small Animal Practitioner*. Teton New Media, Wyoming. 106p.
- Van de Water A., Verheyen J., Xhonneux R. & Reneman R.S. 1989. An improved method to correct the QT interval of the electrocardiogram for changes in heart rate. *J. Pharmacol. Methods* 22(3):207-217. <[http://dx.doi.org/10.1016/0160-5402\(89\)90015-6](http://dx.doi.org/10.1016/0160-5402(89)90015-6)> <PMid:2586115>
- Wardlaw J.M. 1985. Respiratory sinus arrhythmia and the vagus. *Lancet* 1(8440):1268-1269. <[http://dx.doi.org/10.1016/S0140-6736\(85\)92331-1](http://dx.doi.org/10.1016/S0140-6736(85)92331-1)> <PMid:2860460>