

## Clinical and pathological study of an outbreak of obstructive urolithiasis in feedlot cattle in southern Brazil<sup>1</sup>

Alexandre Paulino Loretto<sup>2\*</sup>, Luciana Oliveira de Oliveira<sup>3</sup>, Cláudio Estêvão Farias Cruz<sup>2</sup> and David Driemeier<sup>2</sup>

**ABSTRACT.**- Loretto A.P., Oliveira L.O., Cruz C.E.F. & Driemeier D. 2002. Clinical and pathological study of an outbreak of obstructive urolithiasis in feedlot cattle in southern Brazil. *Pesquisa Veterinária Brasileira* 23(1):61-64. Depto Patologia Clínica Veterinária, Universidade Federal do Rio Grande do Sul, Av. Bento Gonçalves 9090, Cx. Postal 15094, Porto Alegre, RS 91540-000, Brazil. E-mail: lorettiufrgsvet3@aol.com

The epidemiology, clinical picture and pathology of an outbreak of urolithiasis in cattle in southern Brazil are described. The disease occurred in August 1999 in a feedlot beef cattle herd. Five out of 1,100 castrated steers were affected. Clinical signs included colic and ventral abdominal distension. White, sand-grain-like mineral deposits precipitated on the preputial hairs. Affected cattle died spontaneously 24-48 hrs after the onset of the clinical signs. Only one animal recovered after perineal urethrostomy. Necropsy findings included calculi blocking the urethral lumen of the distal portion of the penile sigmoid flexure, urinary bladder rupture with leakage of urine into the abdominal cavity and secondary fibrinous peritonitis. Daily water intake was low since water sources were scarce and not readily available. The animals were fed rations high in grains and received limited amounts of roughage. Biochemical analysis revealed that the calculi were composed of ammonium phosphate. A calcium-phosphorus imbalance (0.4:0.6) was detected in the feedlot ration. For the outbreak, it is suggested that contributing factors to urolith formation include insufficient fiber ingestion, low water intake and high dietary levels of phosphorus. No additional cases were observed in that feedlot after preventive measures were established. Similar dietary mismanagement in fattening steers has been associated with obstructive urolithiasis in feedlot beef cattle in other countries.

**INDEX TERMS:** Obstructive urolithiasis, uroperitoneum, cattle, feedlot, ammonium phosphate, southern Brazil.

**RESUMO.**- [Estudo clínico e anatomopatológico de um surto de urolitíase obstrutiva em bovinos confinados na Região Sul do Brasil.] Os aspectos epidemiológicos, clínicos e anatomopatológicos de um surto de urolitíase obstrutiva em bovinos são descritos. A enfermidade ocorreu em agosto de 1999 em um rebanho de bovinos de corte confinados na Região Sul do Brasil. De um total de 1.100 novilhos castrados, cinco foram afetados. O quadro clínico consistia em cólica, distensão abdominal ventral e acúmulo de material esbran-

quiçado, arenoso, aderido aos pêlos da bainha prepucial. Os animais afetados morriam espontaneamente 24-48h após o início dos sinais clínicos. Um animal se recuperou após uretostomia perineal. Os achados de necropsia incluíam a presença de urólitos obstruindo a luz uretral na porção distal da flexura sigmóide peniana, ruptura da bexiga com extravasamento de urina para a cavidade abdominal e peritonite fibrinosa difusa. O consumo diário de água era pequeno devido à escassez e acesso limitado às fontes hídricas. Os novilhos recebiam alimentação rica em grãos e pobre em forragem. A análise química revelou que os cálculos urinários eram formados por fosfato e amônio. Um desequilíbrio na relação cálcio-fósforo (0,4:0,6) foi constatado através da análise da ração utilizada. No presente relato, sugere-se que os fatores associados com a formação de urólitos foram o fornecimento insuficiente de fibra, a ingestão limitada de água e os níveis elevados de fósforo da ração. Não foram observa-

<sup>1</sup>Accepted for publication on January 30, 2003

<sup>2</sup>Departamento de Patologia Clínica Veterinária, Faculdade de Veterinária, Universidade Federal do Rio Grande do Sul (UFRGS), Av. Bento Gonçalves 9090, Cx. Postal 15094, Porto Alegre, RS 91540-000, Brazil. \*Autor para correspondência, e-mail: lorettiufrgsvet3@aol.com

<sup>3</sup>Hospital de Clínicas Veterinárias (HCV), UFRGS, Porto Alegre, RS, Brazil.

dos mais casos da enfermidade após o estabelecimento de medidas para prevenir a ocorrência de urolitíase neste rebanho. De forma semelhante, erros de manejo na alimentação de bovinos confinados têm sido associados à ocorrência de urolitíase em outros países.

TERMOS DE INDEXAÇÃO: Urolitíase obstrutiva, uroperitônio, bovinos, confinamento, fosfato, amônio, Região Sul do Brasil.

## INTRODUCTION

Obstructive urolithiasis means the formation of calculi in the urinary tract with subsequent urinary blockage by uroliths (Emerick 1988, Payne 1989, Radostits et al. 2000). It appears to affect equally both sexes, but urinary blockage is an important problem only in males. Steers are most commonly affected by the obstructive form of the disease because of the anatomical conformation of their urinary tract (Emerick 1988, Larson 1996, Radostits et al. 2000). Urinary calculi formation usually results from a combination of physiologic, nutritional and management factors. It is mainly attributed to excessive or imbalanced intake of minerals (McIntosh 1978, Larson 1996, Radostits et al. 2000). These circumstances occur especially in feedlots with fattening cattle receiving rations high in cereal grains and oil meals. These feedstuffs contain phosphorus and magnesium in excess, but relatively low levels of calcium and potassium, predisposing to occurrence of the disease (Payne 1989, Radostits et al. 2000). A calcium-phosphorus imbalance results in high urinary phosphate excretion which is an important factor in the genesis of phosphate calculi (Radostits et al. 2000). Numerous additional factors have been incriminated as contributing causes for the development of phosphate calculi with resultant obstructive urolithiasis in cattle. These include heavy concentrate-low roughage diets, limited water intake, deprivation of water or dehydration, urine alkalinity, mineralized artesian water, alkaline water supplies, excess of sodium bicarbonate in the diet, vitamin imbalances e. g. hipovitaminosis A and hypervitaminosis D, and high-protein rations (Emerick 1988, Larson 1996, Radostits et al. 2000). Less frequent types of uroliths include those composed of silica, carbonates or oxalates (Larson 1996). Livestock grazing in areas in which pasture plants contain large quantities of oxalate, estrogens or silica are prone to develop these types of calculi (Radostits et al. 2000). Urolithiasis in castrated beef cattle associated with diethylstilbestrol implants was reported in only one single occasion (Clotilde et al. 1980).

The formation of urinary calculi results when inorganic or organic urinary solutes are precipitated out of solution as crystals or amorphous deposits (Radostits et al. 2000). The mucoprotein which may act as a cementing agent favoring the formation of calculi may be increased in the urine of feeder steers fed heavy concentrate-low roughage rations or pelleted rations (Radostits et al. 2000). Deficiencies in several macromolecules that inhibit crystallization of matrix in urine have also been suggested as a contributory factor to calculogenesis (Griffin 1998, Atmani & Khan 1999). Uroliths have been linked to nanobacterial infection but dietary factors influence their progression (Ciftcioglu et al. 1999).

Fatality rate of urolithiasis in male cattle due to rupture of the urethra or urinary bladder and the economic impact of this condition has been extensively reported in field and slaughterhouse studies developed in many countries (Gasthuys et al. 1993, Radostits et al. 2000). Occurrence of calculi has been associated with lower weight gain and lighter carcasses (Huntington & Emerick 1984). Similar information is not available for Brazilian feedlot cattle herds. Obstructive urolithiasis has been infrequently reported in beef cattle in south-eastern and central Brazil (Lemos & Silveira 2002). Relevant data concerning composition of basal diet, mineral constitution of urinary calculi and influence of the disease on weight gain and carcass characteristics at slaughter are not available (Clotilde et al. 1980, Vianna et al. 1984, Salvador et al. 1999, Lemos & Silveira 2002). Effective prevention measures of this metabolic disorder in these areas rely on knowledge of the major causative factors of the disorder and the circumstances in which they occur.

The present report describes additional cases of obstructive urolithiasis that occurred as a single outbreak in a beef feedlot in southern Brazil and highlights the importance of appropriate nutrition for the prevention of urolithiasis in feedlots.

## MATERIALS AND METHODS

Information regarding signalment, history, clinical findings and nutritional management were retrieved from the owners and staff of the establishment. Five animals with urolithiasis died spontaneously and were necropsied. One affected animal required surgical intervention at the university veterinary hospital (HCV, UFRGS, Porto Alegre, RS, Brazil). Samples of the concentrate and urethral calculi were submitted for analysis. The uroliths were chemically analyzed using a commercial kit<sup>4</sup>. Each ingredient of the feedlot ration was analyzed according to methods previously described elsewhere (Tedesco et al. 1995). All those samples were submitted to analysis in local testing laboratories<sup>5</sup>. Blood and urine analyses were not done.

## RESULTS

The disease was observed in August 1999 in a feedlot beef cattle herd which was situated in the county of Belém Novo, state of Rio Grande do Sul, southern Brazil. The feedlot was composed of 1,100 growing-finishing castrated steers between 1 and 2 and a half years of age, five of those were affected by obstructive urolithiasis and died spontaneously after a clinical course of approximately 2 days. The animals were confined in paddocks and fed a diet composed of grain products i. e. wheat, corn, barley, pelleted rice bran and soybean oil meal. Mineral

<sup>4</sup>Bioclin®, Quibasa Química Ltda, Rua Teles de Menezes 92, Santa Branca, Belo Horizonte MG, 31565-130, Brazil. Tel. (0xx31) 3427-5454, fax (0xx31) 3427-2999. E-mail: bioclin@bioclin.com.br

<sup>5</sup>Laboratórios CEPAV® Tecnologia em Saúde Animal, Rua Tanabi 185, São Paulo, SP 05002-010, Brazil. E-mail: info@cepav.com.br (urolith analysis); Laboratório de Análises de Solo/Laboratório de Nutrição Animal, Departamento de Solos, Faculdade de Agronomia, UFRGS, Av. Bento Gonçalves 7712, Porto Alegre, RS 91540-000, Brazil. E-mail: pa100378@ez-poa.com.br (feedlot ration analysis).

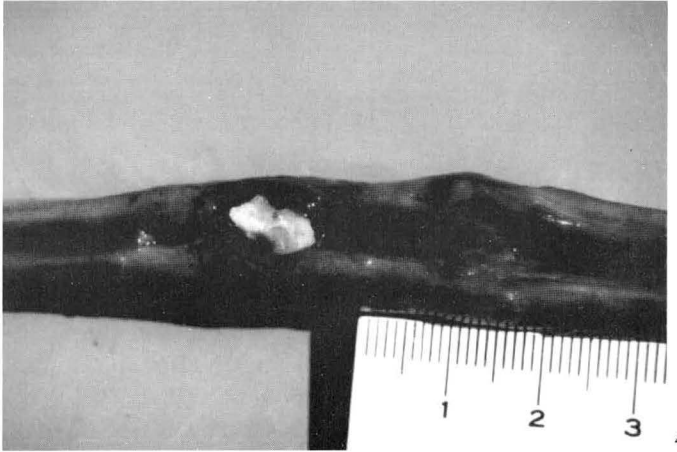
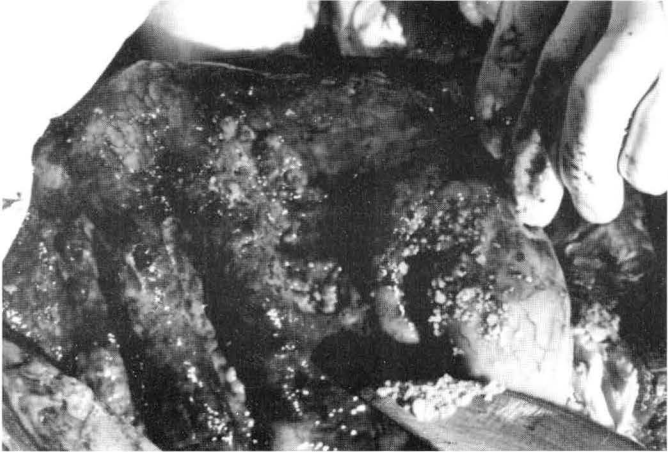


Fig. 1. General view of the feedlot in which an outbreak of urolithiasis occurred. A steer is drinking standing water from a shallow pool formed after rain. Sources of freshwater are scarce and of difficult access. Closer view on the upper right (inset).

Fig. 2. Gritty mineral deposits (uroliths) measuring 0.1-0.2 mm precipitated on the preputial hairs of a steer from the feedlot in which the outbreak of urolithiasis occurred.

Fig. 3. Urinary bladder of a steer from the feedlot in which the outbreak of urolithiasis occurred. The bladder mucosa is irregular, thickened and diffusely congested and hemorrhagic. There are many uroliths scattered throughout the mucosa.

Fig. 4. Penis of a steer from the feedlot in which the outbreak of urolithiasis occurred. There is an urolith of 0.5 cm in diameter studded in the urethral lumen, at the distal portion of the sigmoid flexure, obstructing the urine flow completely.

supplementation and monensin were mixed with the ration. Additionally, cattle were fed small amounts of oat or perennial ryegrass hay. The principal natural source of fresh water was of difficult access due to adverse local geographic features. Therefore, water from pools formed after rain served as the only immediate water supply for the animals (Fig. 1). Other metabolic diseases such as acute grain overload, laminitis and depraved appetite (pica) were also observed in this feedlot.

Clinical signs of partial or total occlusion of the urinary flow by uroliths included uneasiness, abdominal pain manifested by straining, kicking at the belly, repeatedly lying down and rising, rolling, falling and moaning, swishing of the tail and twitching of the penis. The abdomen of those animals became increasingly ventrally and bilaterally distended ("water belly") and there was swelling of the perineum. Close observation of the preputial sheath revealed white, gritty calculi

of 0.1-0.2 cm in diameter precipitated on the preputial hairs from both affected and clinically normal animals (Fig. 2). Death ensued 24-48 hrs after the onset of the clinical signs. At necropsy, there was diffuse, acute, severe fibrinous peritonitis due to rupture of the urinary bladder and leakage of urine into the abdominal cavity (uoperitoneum). The peritoneal cavity was distended with large amounts of clear fluid with a strong smell of urine. Thick layers of fibrin covered the serosa of the abdominal organs and the peritoneum. Two animals presented numerous white, irregular calculi of 0.1-0.2 cm in diameter in the lumen of the ruptured urinary bladder (Fig. 3). Larger, white-yellow, irregular calculi of 0.5 cm in diameter were studded in the urethral lumen at the distal portion of the sigmoid flexure, on the insertion of the retractor muscle of the penis (Fig. 4). Urocystitis was evident as the cranial dorsal wall of the ruptured bladder was extensively vivid red (Fig. 3). One affected animal

recovered completely after surgical removal of the calculi obstructing the urethra through perineal urethrostomy. The biochemical analysis of uroliths revealed the presence of ammonium phosphate. Ca:P imbalance of 0.4:0.6 was found in the concentrate ration. No clear seasonal influences or changes in the weather that would coincide with the occurrence of that outbreak of urolithiasis were demonstrated.

## DISCUSSION

Urolithiasis occurs in all species but the problem assumes greatest economic importance in fattening steers being fed heavy concentrated rations (Radostits et al. 2000). The incidence of bovine urolithiasis has decreased worldwide in recent years because of the improvement in the management of cattle (Larson 1996). Although the occurrence of obstructive urolithiasis is usually sporadic, outbreaks affecting a large number of animals have been recorded (Manning & Blaney 1986, Radostits et al. 2000). In the beef feedlot studied here, after the introduction of adequate amounts of fiber feedstuff in the diet of the feedlot, no additional cases of urolithiasis or other metabolic disorders were observed. It is suggested that important contributing factors for the development of obstructive urolithiasis in that feedlot included rations with high levels of phosphorus, diminished water intake and dietary deficiency or lack of adequate amounts of fiber.

Rupture of the urinary bladder secondary to complete urethral obstruction by uroliths with leakage of urine into the abdominal cavity causes gradual accumulation of fluid from uroperitoneum resulting in a severely distended abdomen as suggested in the present report (Oehme & Tillmann 1965, Radostits et al. 2000). Osmotic pressure from hypertonic urine together with acute fibrinous peritonitis promotes rapid movement of large amounts of extracellular water into the peritoneal cavity resulting in abdominal distension and dehydration. Chemical peritonitis associated with uroperitoneum (Oehme & Tillmann 1965) and cardiovascular disturbances caused by the abnormally high thoracic pressure induced by the abrupt release of large quantities of urine to the abdomen (Gasthuys et al. 1993) could also have contributed to some extent to the death of the animals.

In the present report, ammonium and phosphate were the principal mineral components of the uroliths. Phosphate calculi have usually been described as smooth, soft, numerous, small, sand-like particles (Larson 1996). Both chemical and morphologic findings from our cases match with those from previous reports of phosphate urolithiasis in feedlot cattle (Emerick 1988, Larson 1996). Chemical composition of uroliths together with environmental and dietary factors should be considered when establishing adequate preventive measures for urolithiasis.

The treatment of obstructive urolithiasis is primarily surgical (Larson 1996, Van Metre et al. 1996). Perineal urethrostomy resulted in complete recovery of one animal from that herd. It should be emphasized that immediate slaughter for salvage is advisable when urethral obstruction is diagnosed since therapy for this condition is unrewarding. Critical preventive measures such as providing a calcium to

phosphorus ratio of 2:1 in the complete ration, increasing the salt level to 4% of the diet in order to stimulate water consumption and to increase urine volume and the maintenance of adequate and abundant water supplies should be highly considered in feedlot management.

**Acknowledgements.**— The authors would like to thank Mr. Joel Machado, undergraduate student of veterinary medicine, Universidade Federal de Pelotas, RS, Dr. Fábio Alexandre Rigos Alves, Laboratórios CEPAV Tecnologia em Saúde Animal, São Paulo, SP, Dr. Alexandre de Mello Kessler, Laboratório de Nutrição Animal, and Dr. Clesio Gianello, Laboratório de Análise de Solo, Universidade Federal do Rio Grande do Sul, Porto Alegre, RS, for their technical assistance. Financial support was entirely provided by the Conselho Nacional para o Desenvolvimento Científico e Tecnológico (CNPq-PRONEX), Brazil.

## REFERENCES

- Atmani F. & Khan S.R. 1999. Role of inter-alpha-inhibitor and its related proteins in urolithiasis. Purification of an inter-alpha-inhibitor related protein from the bovine kidney. *Urol. Res.* 27: 57-61.
- Ciftcioglu N., Bjorklund M., Kuorikoski K., Bergstrom K. & Kajander E.O. 1999. Nanobacteria: an infectious cause for kidney stone formation. *Kidney Int.* 56: 1893-1898.
- Clotilde E.M.P., Cappelaro D.M., Nobre D. & Campedelli F<sup>o</sup>, O. 1980. Contribuição ao estudo da urolitíase em bovinos. *Biológico*, São Paulo, 46:77-80.
- Emerick R.J. 1988. Urinary calculi, p.523-528. In: Church, D.C. (ed.) *The Ruminant Animal: Digestive Physiology and Nutrition*. Prentice Hall, New Jersey.
- Gasthuys F. Steenhaut M., De Moor A. & Sercu K. 1993. Surgical treatment of urethral obstruction due to urolithiasis in male cattle: a review of 85 cases. *Vet. Rec.* 133:522-526.
- Griffin D. 1998. Feedlot diseases. *Vet. Clin. North Am. Food Anim. Pract.* 14:199-231.
- Huntington G.B. & Emerick R.J. 1984. Oxalate urinary calculi in beef steers. *Am. J. Vet. Res.* 45:180-182.
- Larson B.L. 1996. Identifying, treating, and preventing bovine urolithiasis. *Vet. Med.* 91: 366-377.
- Lemos R.A. & Silveira A.C. 2002. Urolitíase e ruptura de bexiga, p.213-220. In: Lemos R.A., Barros N. & Brum K.B. (ed.). *Enfermidades de Interesse Econômico em Bovinos de Corte: perguntas e respostas*. Editora UFMS, Campo Grande, MS.
- Manning R.A. & Blaney B.J. 1986. Epidemiological aspects of urolithiasis in domestic animals in Queensland. *Aust. Vet. J.* 63:423-424.
- McIntosh G.H. 1978. Urolithiasis in animals. *Aust. Vet. J.* 54: 267-271.
- Oehme F.W. & Tillmann H. 1965. Diagnosis and treatment of ruminal urolithiasis. *J. Am. Vet. Med. Assoc.* 147:1331-1339.
- Payne J.M. 1989. *Metabolic and Nutritional Diseases of Cattle*. Blackwell, Oxford, p.41-44.
- Radostits O.M., Blood D.C., Gay C.C. & Hinchcliff K.W. 2000. *Veterinary Medicine: a textbook of the diseases of cattle, sheep, pigs, goats and horses*. Baillière Tindall, London. 1877 p.
- Salvador S.C., Mesquita Neto F.D., Pereira G.C. & Macedo C.D. 1999. Ocorrência de urolitíase em bovinos castrados no sul de Minas Gerais. *Arqs Inst. Biológico*, São Paulo, 66 (Suppl.), Resumo 156.
- Tedesco M.J., Gianello C., Bissani C.A., Bohnen H. & Volkveiss S.J. 1995. Análise de Solo, Plantas e outros Materiais. Depto Solos, UFRGS, Porto Alegre. 174 p.
- Van Metre D.C., House J.K., Smith B.P., George L.W., Angelos S.M., Angelos J.A. & Fecteau G. 1996. Obstructive urolithiasis in ruminants: medical treatment and urethral surgery. *Comp. Cont. Educ.* 18:317-328.
- Vianna L.F.C.G., Pinto L.F. & Nogueira F.R.C. 1984. Ocorrência de urolitíase em bezerros semiconfinados. *Arqs Univ. Fed. Rur. Rio de J.* 7:165-169.